

Full Length Research Paper

Effects of *Cucumis metuliferus* E Mey. Ex Naud (Cucurbitaceae) fruit extract on some male reproductive parameters in adult rats

Noel N. Wannang^{1*}, Nanloh S. Jimam¹, Steven S. Gyang¹, Bukata B. Bukar¹ and Saleh Gotom²

¹Department of Pharmacology and Clinical Pharmacy, Faculty of Pharmaceutical Sciences, University of Jos, Nigeria.

²Department of Human Anatomy, Faculty of Medical Sciences, University of Jos, Nigeria.

Accepted 03 December, 2010

The effect of the extract of *Cucumis metuliferus* fruit on some male reproductive parameters was investigated in albino rats. The LD₅₀ of the extract was above 5000 mg/kg body weight when administered orally. Histological studies showed that there was no remarkable change in the testes histology compare to the control. The effects on sperm cells showed a statistically significant (P<0.05) increase in total sperm count with an insignificant (P>0.05) increase in viability count in rats treated with 500 mg/kg dose point. On the other hand, 1000 mg/kg dose point produced significant (P<0.05) decrease in total sperm count and viability count compare to control. This result suggests that *C. metuliferus* fruit extracts could be beneficial in increasing sperm/seminal integrity.

Key words: *Cucumis metuliferus*, sperm count, sperm viability count, testes, male adult rats.

INTRODUCTION

Cucumis metuliferus E. mey. Ex. Naud (Cucurbitaceae) also called 'African horned cucumber', 'melano', 'Jelly melon', or 'kiwano', is a monoecious, climbing annual herb, with staminate flowers typically appearing several days before pistillate flowers (Morton, 1987). The fruits are ovoid berries of between 8 and 10 centimeter long, 4 and 5 cm in diameter, reddish orange at maturity, hanging, covered with strong spiny out-growth, and the seeds are embedded in the mesocarp which is emerald green, with juicy and bland-tasting tissues (Benzioni et al. 1993). It occurs in tropical Africa, especially Nigeria, Botswana, South Africa, Namibia, Zimbabwe and Malawi (Morton, 1987).

In some areas of Plateau state of Nigeria, the fruit pulp of the plant is used by traditional healers for the management of various ailments including peptic ulcer disease, diabetes mellitus, hypertension and HIV/AIDS (Personal communication, 2006). It is believed that the fruit pulp is useful in all diseases-hence the local name kanda (literally meaning 'stop it before it comes. ie as a

vaccine). It is an adjunct in the treatment of 'watery sperm' in males. The plant is widely eaten by many African population as food supplements as it is also claimed to possess antihelmintic activity (Bruecher, 1977; Keith and Renew, 1975; Chiej, 1984). The fruit pulp was found to possess alkaloids, flavanoids, glycosides (Jimam, 2008), which are known to produce biological activity. Information on toxicological studies done on the plant material is not much, however, Wannang et al. (2007) demonstrated that the extract altered serum enzymes in laboratory animals.

This study aims to investigate the effect of sub-chronic administration of the fruit pulp extract of *C. metuliferus* on some sperm indices of adult male albino rats, to establish the rationale for its inclusion in traditional preparations in the treatment of 'watery sperm' and to investigate any possible toxicity (if any) of the plant on male reproduction.

MATERIALS AND METHODS

Collection and identification of the plant

The ripened fruits of the non-bitter variety of *C. metuliferus* were harvested from the fields around Rukuba Barrack Road and

*Corresponding author. E-mail: nnwannang1@yahoo.com. +234 – (0) – 803 – 787 – 7988.

Table 1. LD₅₀ estimation.

1 st investigation	
Treatment (mg/kg)	No. used/no. dead
10	3/0
100	3/0
1000	3/0
2 nd investigation	
Treatment (mg/kg)	No. used/no. dead
1500	1/0
3000	1/0
5000	1/0

Babale village of Jos North, Plateau State, Nigeria, in September, 2006. The plant was identified and authenticated by D .L. Wonang of the Department of Botany, University of Jos, Nigeria. The voucher specimen CCM1 was deposited at the Herbarium of Department of Pharmacognosy, University of Jos, Nigeria.

Preparation of *C. metuliferus* plant material

The ripened fruits were collected and cut open with a sharp edge. The pulp was carefully scooped out using clean spatula. The yellowish fibrous part was carefully separated by maceration and then sun-dried. The seeds were separated from the pulp using a sieve size of 0.25 mm, after thorough stirring. The resulting fluidy content was then spread on trays and dried at 68°C for 24 h in a hot air oven, and then reduced to powder together with the yellowish fibrous portion using pestle and mortar. The powdered fruit pulp was then stored in an airtight container at room temperature till required for use. Distilled water was used to dissolve the powder to form a solution prior to administration.

Animals

Healthy male adult albino rats (Wistar strain) weighing between 150 and 260 g were obtained from the Animal House of the University of Jos, Nigeria. The animals were housed under standard environmental conditions, and feed and water were provided ad libitum. Proper handling and using of the animals were in accordance with the guidelines and regulations, monitored and approved by the Ethical Committee on Animal use, Department of Pharmacology, University of Jos, Nigeria.

Acute toxicity studies (LD₅₀)

The method of Lorke (1983) was used to investigate the oral dose of *C. metuliferus* extract that produced immediate or acute toxicity in rats. The animals were divided into three groups of three rats each and treated with respective doses of 10, 100 and 1000 mg/kg body weight of the aqueous extract of *C. metuliferus* by the oral route. In the second investigation (after 24 h), 3 groups were used with 1 (one) animal per group. The following doses were used: 1500, 3000 and 5000 mg/kg respectively. Animals were observed on hourly basis for the first day and afterwards, daily for four more days. Mortality or any visible sign of injury were recorded.

Effects on sperm

The rats were weighed and randomly allocated into three groups of four animals each. Animals in group 1 (control group) were orally

given distilled water equivalent to 1 ml/100 g, while animals in groups 2 and 3 were orally administered 500 and 1000 mg/kg of the extract dissolved in distilled water respectively daily for 28 days.

At the end of 28 days, the rats were sacrificed by chloroform anaesthesia and their scrotum dissected to expose the testis and epididymis. The epididymic portion attached to the posterior surface of the testis was cut and the sperm/ semen collected for microscopical examinations (magnification: x400) and the number of forward moving sperms cells were counted. The testes were also removed and preserved in 10% (v/v) formalin. Tissues from this organ were sectioned 5 microns thick in paraffin wax, after which they were deparaffinised and stained with mayer hematoxylin and eosin stains for qualitative microscopic assessment.

Statistical analysis

Results were all expressed as mean + SEM and all data obtained were statistically analyzed using student's t-test and values of P<0.05 were considered significant.

RESULTS

The result of the LD₅₀ showed that there was no any incidence of death from the test in the animals administered the various oral doses (10 - 5000 mg/kg body weight) as seen in Table 1.

The result shows statistically significant (P<0.05) increase in the total sperm count with an insignificant (P>0.05) increase in viability count after daily oral administration of 500 mg/kg for 28 days compared to the control. There was an insignificant (P>0.05) decrease in the number of death sperms at the same dose. However, the decrease in total sperm count and viability counts as a result of 1000 mg/kg administered were statistically significant (P<0.05) compared to the control, while the decrease in the number of death sperms after 1000 mg/kg was not significant (P>0.05) compared to control (Table 2). Histological studies of the testes of the rats treated with oral doses of 500 mg/kg and 1000 mg/kg body weight for 28 days showed no remarkable changes in the sertoli/leydig cells compared to the control (Figures 1 - 3).

DISCUSSION

The use of herbal medicine as therapeutic agents for the treatment of ailments, particularly in the developing countries has continued to yield fruitful results. It has been reported that not less than 80% of the African population depend on traditional medicine to meet up their Primary Health Care needs (Sam, 2004). These herbal preparations are mostly used in their crude forms; hence, there is possibility of toxic effect, which is of medical concern (Pak et al., 2004; Chan, 1997).

The LD₅₀ gives a measure of the immediate or acute toxicity of a test substance (Lorke, 1983), and was established to be within the 'safe' limit according to Dubors and Gelling (1959). It was observed that increasing the doses of the aqueous extract of *C. metuliferus* up to 5000 mg/kg, orally, was not lethal, which was an indication that

Table 2. Effect of *C.metuliferus* fruits on sperm/semen integrity in male rats

Treatment (mg/kg)	Sperm count		
	Viable	Death	Total
Control	131.67 + 9.42	35.00 + 3.02	166.67 + 11.89
500	136.67 + 6.25	33.33 + 5.69	170.00 + 0.71*
1000	97.33 + 3.88 *	29.00 + 4.08	126.33 + 4.71

* $P < 0.05$ compared to control; n = 5

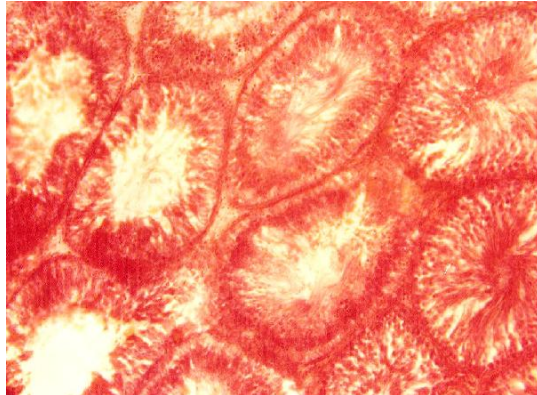


Figure 1. Normal testes histology of rat (control)




Figure 3. Testes of rat treated with extract (1000 mg/kg)




Figure 2. Testes of rat treated with extract (500 mg/kg)

the extract is very safe (Lorke, 1983; Askari et al., 1996). It may not be conclusive that the plant material does not have deleterious effects on some vital organs, thus, more toxicological evaluation are going on in our laboratory. The development of normal and mature sperm is the key to optimum male fertility. The production of the sperm cells (spermatozoa) and testosterone in the testes are mainly regulated by the follicle stimulating hormone (FSH) and luteinizing hormone (LH), which are released from the anterior pituitary (Steinberger, 1971). FSH stimulates spermatogenesis in the sertoli cells, while LH stimulates the production of testosterone in the leydig cells of the testes (Lacy, 1967; Kerr and Klester, 1975). It

has also been demonstrated that the proliferation of spermatogonia in mammals and birds is FSH-stimulated (Steinberger et al., 1964; Mancini et al., 1967; Krueger et al., 1974). Spermatogenesis is, therefore, a complicated process, covering proliferation of the spermatogonia, long-lasting process of the tissue meiosis and numerous changes in the spermatids during their pre-formation (Steinberger, 1971; Kerr and Klester, 1975).

The results from this work showed absence of damages on the sertoli/leydig cells after 28 days continuous oral administration of 500 and 1000 mg/kg body weight. Sexual cells can occur during the reproductive period-mitotic division of the spermatogonia, or during the maturation of the spermatozoa, thereby affecting the number and quality of the sperm cells produced. 500 mg/kg of the extract produced an increase in total sperm count and viable sperms, while 1000 mg/kg decreased (but not significantly) both the viable and total sperm counts. This may be as a result of the ability of the extract at the given doses, to either interfere with spermatogenic processes in the seminiferous tubules, Epididymal functions or activities of testosterone on hypothalamic release factor and anterior pituitary secretion of gonadotropins which may result in alteration of spermatogenesis (William, 2000; Bowman and Rand, 1985). The presence of immature sperms was also observed in the experimental rats treated with the 1000 mg/kg daily dose of extract of *C. metuliferus*. This suggests that the 1000 mg/kg dose point could affect the maturation of the spermatozoa in the male rats, which might also be a contribu-

tory factor to the decrease in the mean total sperm count. Preliminary phytochemical analysis of the plant extract revealed the presence of alkaloids, glycosides, tannins, flavonoids (Jimam, 2008). These materials may be responsible for the biological activity. Work is on going in our laboratory to ascertain the ingredient that is responsible for activity.

ACKNOWLEDGEMENT

The authors acknowledge the contribution of the staff of the Departments of Human Physiology, Human Anatomy, University of Jos, Nigeria, and staff of the Chemical Pathology Department of Jos University Teaching Hospital, Jos, Nigeria.

REFERENCES

- Askari A, Nirza M, Solangi MSP (1996). Toxicological Studies of herbal beverages and seeds extract of *Hibiscus sabdariffa* L. (Roselle). Pakistan Sciences and Industrial Research, 391 (38):1-4
- Benzioni A, Mendlinger VM, Huyskens S (1993). Germination, fruits development, yield and post harvest characteristics of *C. metuliferus*. In: Janick J. Simon JE (eds) New crops. Wiley, New York. pp. 553-557.
- Bowman WC, Rand MJ (1985). The Reproductive system and drugs affecting the reproductive systems. Textbook of Pharmacology, 2nd edition, 20: 1-8.
- Bruecher H (1977). Cucurbitaceae. In: Tropische Nutzpflanzen. Springer verlag, Berlin. p. 258 – 297.
- Chan TY (1997). Monitoring the safety of herbal medicines, Drug Safety 17: 209-215.
- Chiej R (1984). Encyclopaedia of Med. Plants. MacDonald.
- Dubors KP, Gelling M (1959). Textbook of Toxicology. Oxford University Press. p.302
- Jimam NS (2008). Some pharmacological and Toxicological evaluation of *Cucumis metuliferus* in laboratory animals. M.Sc thesis. University of Jos, Nigeria
- Keith ME, Renew A (1975). Notes on some edible plants found in the Kalahari. Gemsbok Park. Koedoe, 18: 1-12.
- Kerr JB, Klester DM (1975). Cyclic variation in sertoli cell lipid content throughout the spermatogenic cycle in the rats. Journal of Reproduction and Fertility, 43(1):1-8.
- Krueger PM, Hodgen CD, Sherins KI (1974). New evidence for the role of the sertoli cells and spermatogonia in feedback control of FSH-secretion in male rat. Endocrinology, 95(4): 955-962.
- Lacy D (1967). The seminiferous tubule in mammals. Endeavour, 26, 101-108.
- Lorke D (1983). A new approach to practical acute toxicity testing. Archive Toxicology, 54: 275-287.
- Mancini RE, Castro A, Serguer AC (1967). Histological localization of follicle-stimulating and luteinizing hormones in the rat testis. J. Histochem. Cytochem. 15(9):516-526.
- Morton JF (1987). The horned cucumber alias "Kiwano" (*Cucumis metuliferus*, cucurbitaceae). Econ. Botany, 41: 325-326.
- Pak E, Esrason KJ, Wu VH (2004). Hepatotoxicity of herbal medicines: An emerging dilemma prog. Transplant 14: 91-96.
- Sam B (2004). Can Traditional Medicine help AIDS? Institute of Science in Society Press Release. (file://pc 2/my % 20 documents/aids 4.htm).
- Steinberger E (1971). Hormonal control of mammalian Spermatogenesis. Physiology Review, 5111: 1-22.
- Steinberger E, Steinberger A, Perloff WH (1964). Initiation of spermatogwgenesis invitro. Endocrinology, 74: 788.
- Wannang NN, Jimam SN, Omale S, Dapar LMP, Gyang SS, Aguiyi JC (2007). Effects of *Cucumis metuliferus* (cucurbitaceae) fruits on enzymes and haematological parameters in albino rats. African J. Biotech. 6(22):2515-2518
- William KN (2000). Hormones and Hormone antagonists. In: Remington, The Science and Practice of Pharmacy, vol. II, 20th edition, 77: 1390 – 1391.