

Full Length Research Papers

Evaluation of the fallopian tubes in infertile women by hysterosalpingography in Tikur Anbessa Hospital, Addis Ababa, Ethiopia

Daniel Admassie and Yewebdar Negatuy

Department of Radiology, Addis Ababa University, Medical Faculty, Addis Ababa, Ethiopia Med J 46:391-5. 2008

Accepted 09 November, 2019

Infertility is a common public health problem especially in sub-Saharan Africa. Hysterosalpingography (HSG) has for many years been employed in the evaluation of infertility for assessment of tubal patency and tubal or intrauterine lesions. The objective of this paper is to evaluate the structural abnormality of the fallopian tubes in infertile women with hysterosalpingography in Tikur Anbessa Hospital (TAH). Retrospective analysis of clinical records of 331 women with infertility problem who underwent HSG in TAH from March 1, 2003 to March 31, 2006 was done. Infertility unit in the Obstetrics and Gynecology Department in collaboration with Radiology Department compiled the data. Primary infertility is more common (60%) than secondary infertility (40%). Tubal pathologies accounted for 261 (78.9%) of the total sample. The age group of 23 to 27 years and 33 to 37 years accounted for the majority of cases of primary and secondary infertility respectively. Tubal pathology accounted for 78.9% of infertility in this study. HSG should continue serving as a valuable means of investigation (imaging modality) in infertile women of reproductive age group related to tubal pathology.

Key words: Infertility, hysterosalpingography, tubal pathologies.

INTRODUCTION

Infertility is the lack of pregnancy (regardless of causes) in sexually active individual after a year or more of unprotected sexual intercourse. Infertility affects approximately 10 to 15% of couples of reproductive age group (Gottesman and Bain, 1980; Farah, 2000). More women with primary rather than secondary infertility seek for medical advice (Farah, 2000). The etiology includes ovulatory dysfunction, tubal or pelvic pathology, the male partner (male factor) and other unexplained causes. Ovulatory dysfunction accounted as an underlying cause of infertility in approximately 30%. Tubal or uterine factors are held responsible for another 20% of infertility and male factors take nearly 40% of the share. Anatomical abnormalities, cervical factors and immunological problems contributed to roughly 5% of cases. The remaining unknown causes by current scientific method are referred to as unexplained infertility (Farah, 2000).

Hysterosalpingography (HSG) is the commonest diagnostic modality in our setting for the workup of infertility

related to tubal and uterine factors. The procedure is done as outpatient within seven days after the onset of menstruation. A water soluble contrast media of 20 ml is instilled into the uterine cavity through the vagina and cervix. The passage of the contrast is screened by fluoroscopy and films are taken to evaluate the tubes and uterine cavity for the presence or absence of congenital or acquired abnormality. During the procedure, a delay film is taken only if necessary after screened by fluoroscopy. Though laparoscopy gives much useful information in addition to that yielded by HSG, HSG remains the commonest diagnostic modality in developing countries where laparoscopy is not easily available as it is a simple outpatient procedure without anesthesia and with minimum morbidity, and relatively low cost (Hutchins, 1977; Grainger et al., 2003; Mosher and Pratt, 1990; Soren, 1980; Elsie and Rosemary, 2004; Horwitz et al., 1979; Holst et al., 1983; Brant et al., 1999; Sutton et al., 2007).

Though HSG do not diagnose pelvic adhesion in up to 30% of the patients and is associated with rare complication such as spotting, fainting, uterine infection and iodine-dye allergy, it also helps purge debris in the

*Corresponding author. E-mail: dadmasie@gmail.com.

fallopian tubes, enabling some infertile women get impregnated (Farah, 2000; Grainger et al., 2003; Sutton et al., 2007; Bell, 2004). Studies conducted in infertile women by Bell (2004), Elsie and Rosemary (2004) and De Muylder (1995) in Nigeria, Uganda and Zimbabwe showed secondary infertility is more common than primary infertility with tubal obstruction being the commonest cause. The purpose of this study is to evaluate the infertile women with HSG and to find structural abnormality of the fallopian tube in our setting and compare with other similar results.

MATERIALS AND METHODS

This is a facility based retrospective review of 331 consecutive patients who underwent hysterosalpingography in Department of Radiology, Tikur Anbessa Teaching Hospital. The review was made by the Department of Radiology from April 1, 2006 to January 31, 2007. All patients who were sent from infertility clinics for HSG after history, physical examination and other identifiable causes were excluded. The card numbers of women who underwent hysterosalpingography were retrieved from referral clinic book of Department of Gynecology and Obstetrics from March 1, 2003 to March 31, 2006. Those cards which contain no adequate information or not available were excluded. Only HSG done in TAH is included in the study. The cards were collected from card room. The clinical notes and the radiological findings were analyzed for demographic data, uterine status, tubal and pelvic pathology. The findings were first recorded on the data sheet format, then transferred into Microsoft excel spread sheet. All data inserted in the excel spread sheet were subjected to descriptive statistics. In addition to HSG findings, the clinical indications, history of patients and other investigations were carefully examined. All patients were examined as outpatients, and got prepared for HSG. The procedure is to be done within seven days after the onset of menstruation. A water soluble contrast medium of 20 ml is instilled into the uterine cavity through the vagina. The passage of the contrast is screened by fluoroscopy and films were taken that showed the uterus and fallopian tubes with peritoneal spillage. During the procedure, a delay-film is taken only if necessary after screened by fluoroscopy

Operational definition

- i. Primary infertility means women who have never conceived.
- ii. Secondary infertility means women who had previous conception.
- iii. Distal occlusion means if the tubes are filled and no peritoneal spillage is noted.
- iv. Delayed film: This is considered if there is retention of contrast material in the fallopian tube 20 minutes after removing the cannula from the cervix is often regarded evidence of obstruction. But if the tubes are filled and no peritoneal spillage is noted, the diagnosis would be distal occlusion.
- v. Hydrosalpinx is defined as dilatation of the ampullary segment of the fallopian tube with associated thinning of adherent fimbriae and destruction of the mucosa.
- vi. Cornual block is defined if no tubal filling was seen during the procedure in different views.
- vii. Tubal obstruction versus bilateral cornual spasm:-radio logically spasm characterized by pointed or irregular margin.

RESULTS

Out of 331, 70 (21.2%) of the women have normal

bilateral fallopian tubes and the remaining 261 (78.9%) have abnormal tubal findings. Out of the 261 abnormal findings, 167 (50.5%) revealed proximal tubal blockage, of which 91 (27.5%) were bilateral and 76 (22.98 %) unilateral blockage.

From among the 94 (28.3%) women who belong to the abnormal cluster, 12 (3.6%) exhibit distal tubal blockage with or without hydrosalpinges due to fimbrial blockage. The rest 82 (24.8%) women of the 94 displayed both proximal and distal tubal blockage with or without hydrosalpinges. Bilateral hydrosalpinges are found to be double the unilateral hydrosalpinges (Table 1).

Young women of ≤ 32 years of age exhibit an exceeding primary infertility. However, over 32 years of age secondary infertility outweigh primary infertility (Figure 1). The highest percentage (17.2%) of proximal tubal blockage was witnessed in women of age range 28 to 32 years and remained high throughout the age ranges.

Those women in the age range of 28 to 32 years showed high percentage of distal tubal blockage with or without hydrosalpinges (Figure 2).

DISCUSSION

Childlessness is a personal tragedy in Africa. Its effect can result in marital instability, suicide and as a result, infertility has become a serious public health issue over the African continent (Bell, 2004). Those patients within 18 to 43 years of age suffered infertility more often than not.

In contrast to the studies made with HSG on infertile women in Kampala, Uganda and Ilorin Nigeria, where secondary infertility was more common than primary one (Elsie and Rosemary, 2004; Bell, 2004; Kitilla, 2000), this study revealed that primary infertility is more common than secondary infertility. The study made by Kitilla in Ethiopia and Larsen in sub Saharan African showed that the primary infertility is more common than the secondary one (Kitilla, 2000; Larsen, 2000). However, other studies like by Holst et al. (1983) and Cambell and Roberts (1974) in Papua New Guinea and the one in Florida found that primary infertility is more common than secondary one (Farah, 2000). This study has shown that 78.9% of the women had abnormal fallopian tube or tubes. This is lower than 83.4% reported from Uganda and is greater than 71% reported from Nigeria.

Causes of tubal blockage are often sexually transmitted infection, post-abortion, post purperal infections and tuberculosis (Farah, 2000; Kitilla, 2000).

Early sexual practice and a rise in the number of young sex workers can increase the number of cases of tubal pathology (Elsie and Rosemary, 2004). Peri-tubal adhesion, though difficult to conform with HSG, is inferred, when contrast remains loculated round the tube, and not spread in the peritoneum freely or canalized flow is noted (Mosher and Pratt, 1990).

Women in the age range of 33 to 37 years revealed

Table 1. HSG findings distribution of the fallopian tubes among 331 infertile women in Tikur Anbessa Specialized Hospital, March 2003 to 2006.

Findings	Frequency	Percent
Normal	70	21.2
Proximal tubal blockage (PB)*		
Bilateral	91	27.5
Unilateral	76	23.0
Distal tubal blockage with or without hydrosalpinges (DB)*		
Bilateral	8	2.4
Unilateral	4	1.2
Combination of both PB and DB	82	24.8
Total		

*PB=

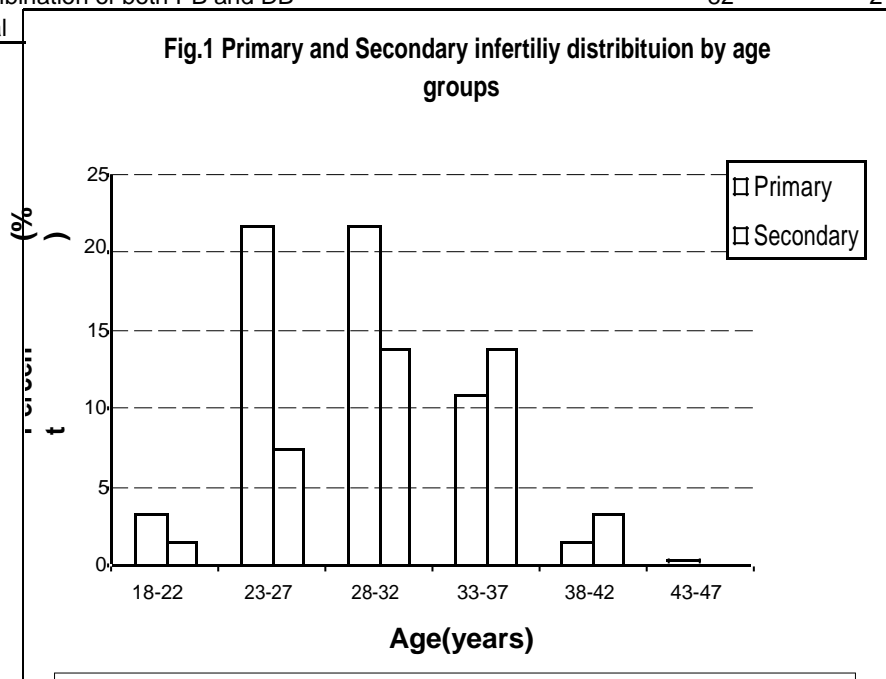


Figure 1. Age group distribution among 331 primary and secondary infertile women and HSG performed in Tikur Anbessa Hospital, March 2003 to 2006.

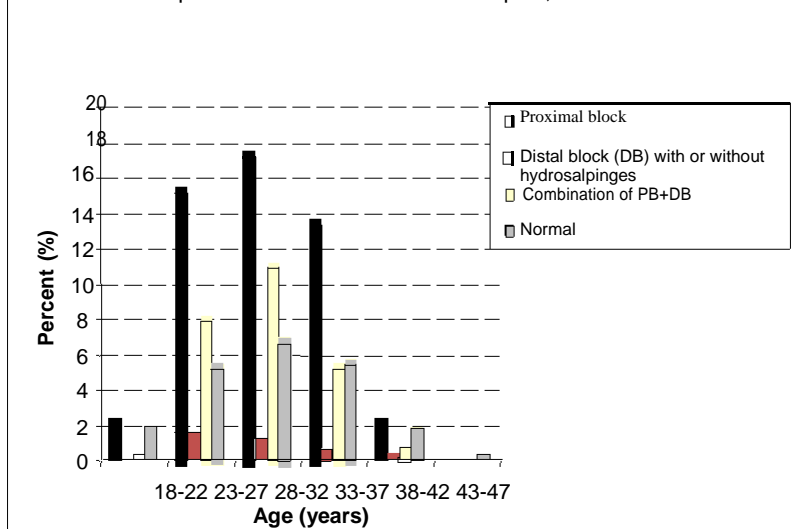


Figure 2. HSG tubal findings among 331 infertile women by age group in Tikur Anbessa Hospital, March 2003 to 2006

more of secondary infertility in Tikur Anbessa but, a study from Uganda reported secondary infertility is common between 26 and 30 years of age (Elsie and Rosemary, 2004).

To put it in a nutshell, primary infertility is more common than secondary infertility in this study and the common cause of infertility has proved to be tubal pathology. In spite of new inventions and advances in imaging modalities, HSG remained to be a symbolic radiological procedure for fallopian tube visualization in areas where adequate facilities are not present. Study that showed structural abnormality of the fallopian tube in infertile women by HSG was not adequately studied in Ethiopia, so this study together with others can serve as a base line for the country.

ACKNOWLEDGEMENTS

The authours would like to thank Ato Negash Mamo for writing and reviewing this manuscript and also Ato Tesfaye Ejegu for editing this manuscript.

REFERENCES

- Bell TO (2004). Pattern of tubal pathology in infertile women on Hysterosalpingography, Ilorin, Nigeria. *J. Med.*, 3(3):77-9.
- Brant E, Helms A, Williams E (1999). *Genital tract*. Brant E. *Fundamentals of Diagnostics Radiology* 2nd ed, USA, 815-16.
- Cambell GR, Roberts-TK (1974). Infertility in the highlands. *Papua New Guinea Med. J.*, 17:347.
- De Muylder X (1995). Role of HSG in the evaluation of infertility in Black Africa. *Med Trop.*, 55(2):160-4.
- Elsie KM, Rosemary KB (2004). Structural findings at hysterosalpingography in patients with infertility at private clinics in Kampala, Uganda. *African Health Sci.*, 4(3): 178-81.
- Gottesman IS, Bain J (1980). Subfertility and infertility in the male: a persistent dilemma. *Dagnostics Androl.*, 107: 79-86
- Grainger RG, Allison D, Andreas A, Dixon AK, Adam A (2003). *Hysterosalpingography: Textbook of Medical Imaging, Diagnostic Radiology*, 4th, London, pp. 2227-2237.
- Holst N, Abyholm T, Borgersen A (1983). Hystero-salpingography in the evaluation of infertility. *Acta Radiol. Diagnosis*, 24: 253-257.
- Horwitz MB, Morton MB, Shaff MI, Hugo A (1979). A radiological approach of infertility on hystero-sapingography. *Br. J. Rad.*, 52: 255-62.
- Hutchins CJ (1977). Laparoscopy and Hysterosalpingography in the Assessment of Tubal patency. *Obstetr. Gynecol.*, 49:325-27.
- Kitilla T (2000). Infertility investigation: socio-demographic characteristics and dropouts of infertile women at Family Guidance Association of Ethiopia. *Ethiop. J. Health Dev.*, 14(2):127-34.
- Larsen U (2000). Primary and secondary infertility in Sub-Saharan Africa. *Int. J. Epidemiol.*, 29: 285-291.
- Mosher W, Pratt W (1990). Fecundity and infertility in the United States, 1965-88. *Adv.Data*.192:192-212.
- Soren SS (1980). Infertility factors: their relative importance and share in an unselected material of infertility patients. *Acta Obstet Gynecol. Scand*, 59:513-20.
- Sutton D, Crofton M, Jenkins J (2007). *The gynecological imaging. Text book of Radiology and Imaging*. 7th ed. London, 1085-90. Vol 2.