

## Full Length Research Paper

# Hepatoprotective effect of *Cichorium intybus* on CCl<sub>4</sub>-induced liver damage in rats

Sadeghi Heibatollah<sup>1\*</sup>, Nikbakht Mohammad Reza<sup>2</sup>; Ghaitasi Izadpanah<sup>2</sup> and Sabzali Sohailla<sup>3</sup>

<sup>1</sup>Department of Biochemistry, Faculty of Medicine, Yasuj University of Medical Sciences, Yasuj –Iran and Herbal Medicine Research Center, Yasuj University of Medical Sciences, Yasuj –Iran. <sup>2</sup>Department of Physiology and Pharmacology, Faculty of Medicine, Yasuj University of Medical Sciences, Yasuj –Iran and Herbal Medicine Research Center, Yasuj University of Medical Sciences, Yasuj –Iran. <sup>3</sup>Imam Sajjad Hospital, Yasuj University of Medical Sciences, Yasuj, Iran.

Accepted 11 April, 2020

The purpose of this study was to evaluate the hepatoprotective activity of hydroalcoholic extract of *Cichorium intybus* (*Cichorium intybus*) using a carbon tetrachloride (CCl<sub>4</sub>) - induced liver injury in rats. The leaf extract at oral dosage of 200, 400 and 500 mg/kg exhibited significant ( $P<0.05$ ) protective effect against CCl<sub>4</sub> induced hepatotoxicity. Level of serum markers such as aspartate aminotransferase (AST), alanine aminotransferase (ALT), alkaline phosphatase (ALP), total bilirubin (TB) were significantly increased in CCl<sub>4</sub> treated rats. Simultaneously, *C. intybus* extract significantly suppressed mainly the increase in plasma activities of AST, ALT, ALP and TB concentration, which are considered as markers of liver functional state. The results of this study confirmed the hepatoprotective activity effect of the hydroalcoholic extract of *C. intybus*.

**Key words:** *Cichorium intybus*, hepatoprotective activity, carbon tetrachloride, aspartate aminotransferase, alanine aminotransferase, alkaline phosphatase.

## INTRODUCTION

Liver diseases are a serious health problem. In the absence of reliable liver protective drugs in allopathic medical practices, herbs play an important role in the management of various liver disorders. A number of plants have shown hepatoprotective property (Scott Luper, 1998). Hepatoprotective effect of some plants like *Crassocephalum crepidioides* (Aniya et al., 2005), *Epaltes divaricata* (Hewawasam et al., 2004), *Aspalathus linearis* (Ulican et al., 2003) and *Sarcostemma brevistigma* (Sethuraman et al., 2003) etc. has been well established. *Cichorium intybus* is referred to “kasni” in Iran and “kasani” in India. It is used for local application in the treatment of acne, inflammation of throat, enlargement of the spleen, diarrhea and vomiting (Jindal et al., 1975). In some regions of Iran the leaves of *C. intybus* have been used as edible vegetable and in some other regions for the treatment of liver disorders (Amin, 1991). A decoction of the leaves has been used in the treatment of jaundice,

liver enlargement, gout and rheumatism (Pushparaj et al., 2007). In recent years many researchers have examined the effects of *C. intybus* roots and seeds on hepatotoxic damages (Zafar and Mujahid, 1998; Ahmed et al., 2003), those of its leaf on cardiac injuries (Nayeemunnisa and Rani, 1998), diabetic and hyperlipidemic disorders (Pushparaj et al., 2007). However, there no scientific studies on the hepatoprotective effects of *C. intybus* leaf extract although used as folk remedy for treatment in some region of Iran. The present study was under taken to evaluate the hepatoprotective ability of *C. intybus* leaf extract in experimental animal.

## MATERIAL AND METHODS

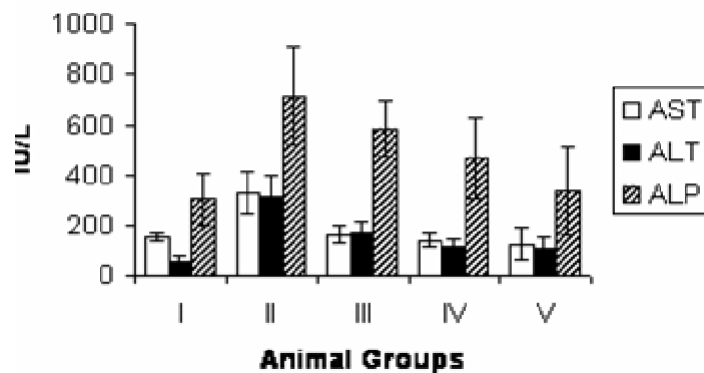
### Chemicals

CCl<sub>4</sub> was obtained from Merck and assay kits for the estimation of biochemical factor were purchased from Pars Azema, Iran.

### Plant extract

The aerial parts of *C. intybus* were collected from Kakan in Yasuj,

\*Corresponding author. E-mail: [hsadeghim@yahoo.com](mailto:hsadeghim@yahoo.com). Tel: +98-741-2233699. Fax: +98-741-2233704.



**Figure 1.** Effect of *C. intybus* leaf extracts on AST, ALT and ALP activities on CCl<sub>4</sub> hepatotoxicity. Group I (control), Group II (CCl<sub>4</sub>), Group III (CCl<sub>4</sub> + 200 mg *C. intybus* crude extract), Group IV (CCl<sub>4</sub> + 400 mg *C. intybus* crude extract) and Group V (CCl<sub>4</sub> + 500 mg *C. intybus* crude extract). Values are mean  $\pm$  S.D. of eight rats/group; the data in group II significantly different from control group ( $P < 0.01$ ); and in groups III, IV, and V significantly differ from group II ( $P < 0.05$ ).

Iran, in the spring, 2005. A voucher specimen was deposited in the herbarium of Kohkyloeyeh and Boyerahmad Agricultural Research Center. The plant leaves were dried far from direct light, and then powdered. The powder was kept in a closed container in 4°C. The powdered material (500 g) was extracted three times (for one day each time) with ethanol-water (1:1, v/v) at room temperature. The accumulated extract was concentrated under reduced pressure and dried. The dried extract was suspended in distilled water and the volume was adjusted to 500 ml (equivalent to 1 g plant powder per ml) (Sadeghi and Yazdanparast, 2003). The concentrated extract was divided into 25 ml aliquots and kept at -20°C for further investigation. The acute toxicity studies were carried out as per stair case method (Mankani et al., 2005) and 500 mg/kg body weight was selected as the therapeutic dose for the evaluation.

#### Experimental procedure

Forty male albino rats of Wistar strain, each weighing 150 - 180 g were purchased from Razi Institute in Shiraz. The animals were assigned to five groups, each consisting of 8 rats. The animal were housed in polypropylene cages and maintained in controlled temperature ( $22 \pm 2^\circ\text{C}$ ) and light cycle (12 h light and 12 h dark). Animals were allowed to take standard laboratory feed and tap water. Group I received only olive oil and served as the control group, and the other groups (group II to V) were intraperitoneally applied CCl<sub>4</sub> as a 50% solution in olive oil (1ml/kg) twice a week for six weeks. Groups I and II received only oral normal saline daily but groups III, IV and V were given *C. intybus* leaf extract at doses of 200, 400 and 500 mg/kg body weight, respectively. Forty five days after CCl<sub>4</sub> administration, and 48 h after last treatment with CCl<sub>4</sub> and *C. intybus* extract, blood was collected by cardiac puncture from all the animals. Serum was prepared from the collected blood and subjected to biochemical measurement of different parameters like AST, ALT, ALP, TB, total protein (TP) and Albumin (Alb) (Sethuraman et al., 2003; Ulican et al., 2003; Hewawasam et al., 2004; Aniya et al., 2005) by standard automated techniques using of Hitachi Analyzer (Model 911) and the adequate kits from pars azema, Iran.

#### Histopathology

A portion of liver tissue in each group of rats was selected and fixed

in 10% formalin diluted with distilled water and processed for paraffin embedding. Sections were stained with hematoxylin and eosin and observed under microscope (Srivastava. and Shivanandappa, 2006).

#### Statistical analysis

All data were expressed as mean  $\pm$  standard deviations, and analyzed using ANOVA (SPSS 10.5 for windows). A value of  $P < 0.05$  was accepted as significant.

## RESULTS

As shown in Figure 1, activities of serum ALT, AST and ALP were markedly elevated in CCl<sub>4</sub> treated animals compared to control group, indicating liver damage. Administration of *C. intybus* leaf extract in three different dosages remarkably prevented CCl<sub>4</sub> induced elevation of serum enzyme in a dose dependent manner. As given in Table 1, the TP and Alb concentrations in CCl<sub>4</sub> treated animals were less in group II animals, compared with the control group and it attained an almost near the normal value in groups which were treated with *C. intybus* leaf extract. There was a significant increase in the concentration of TB in the serum of CCl<sub>4</sub>-treated rats as compared to the control group. Administration of *C. intybus* leaf extract prevented CCl<sub>4</sub>-induced elevation of serum TB (Table 1).

Histopathological study of liver from the control group animals showed a normal hepatic architecture with distinct hepatic cells, sinusoidal spaces and a central vein (Figure 2A). However, CCl<sub>4</sub>-intoxicated treatment exhibited sever histopathological change, such as centrilobular hepatic necrosis, fatty change, apoptotic bodies and ballooning degeneration (Figure 2B). Pretreatment with 500 mg/kg of ethanolic extract of *C. intybus* leaf showed signi-

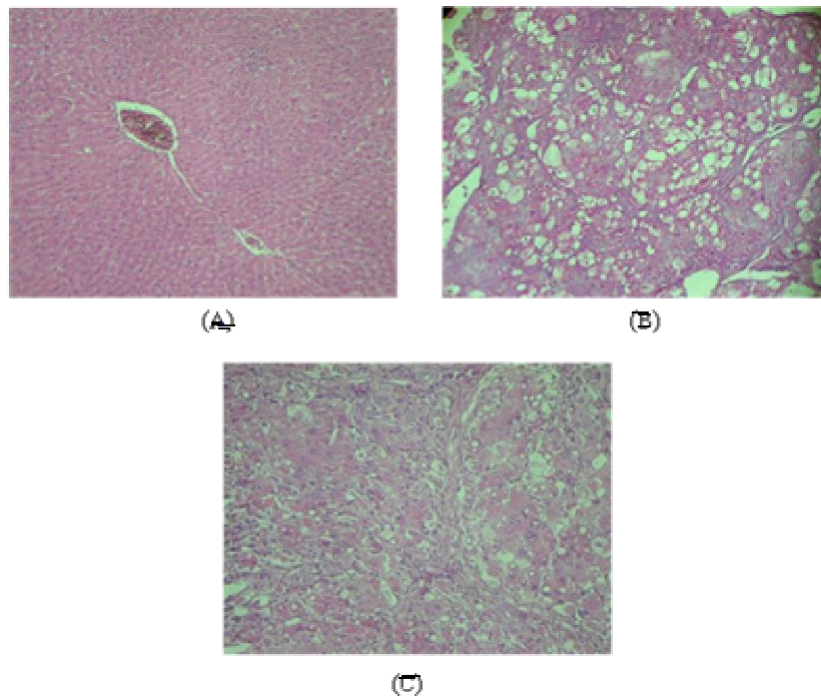
**Table 1.** The effect of *C. intybus* leaf extract on serum levels of TP, Alb and TB in rats subjected to CCl<sub>4</sub> induced hepatotoxicity.

Group	TP (g/dl)	Alb (g/dl)	TB (mg/dl)
Group I ( control)	6.25 ± 0.88	3.35 ± 0.36	0.25 ± 0.1
Group II (CCl <sub>4</sub> )	5.2 ± 0.65	2.67 ± 0.4	2.45 ± 0.86
Group III (CCl <sub>4</sub> + 200mg <i>C. intybus</i> )	5.75 ± 0.67 <sup>**</sup>	2.92± 0.44 <sup>**</sup>	1.45 ± 0.25 <sup>*</sup>
Group IV (CCl <sub>4</sub> + 400mg <i>C. intybus</i> )	6.35 ± 1.19 <sup>**</sup>	3.4 ± 0.42 <sup>**</sup>	0.95 ± 0.17 <sup>*</sup>
Group V (CCl <sub>4</sub> + 500mg <i>C. intybus</i> )	7.02 ± 1.2 <sup>**</sup>	3.45 ± 0.36 <sup>**</sup>	0.52 ± 0.19 <sup>*</sup>

Values are mean ± S.D., n = 8

\* Significant reduction compared to Group II ( $P < 0.01$ ).

\*\* Significant increase compared to Group II ( $P < 0.05$ ).



**Figure 2.** Effect of *C. intybus* extract on CCl<sub>4</sub>-induced hepatotoxicity in rats. (A) Control group; (B) CCl<sub>4</sub>-induced group; (C) CCl<sub>4</sub> group treated with 500 mg/kg *C. intybus* extract. Liver sections were stained with haematoxylin and eosin (200X).

ficant recovery. Ballooning degeneration, fatty change, centrilobular hepatic necrosis and apoptotic bodies in hepatocytes were scarce (Figure 2C).

## DISCUSSION

The efficacy of any hepatoprotective drug is essentially dependent on its capacity of either reducing the harmful effects or maintaining the normal physiologic function which has been disturbed by hepatotoxic agents. Measurement of the activities of serum marker enzymes, like AST, ALT and ALP, can make assessment of liver function (Venukumar and Latha, 2002; Ulican et al., 2003; Porchezian and Ansari, 2005). The changes

associated with CCl<sub>4</sub>-induced liver damage are similar to those of acute viral hepatitis. In the liver, microsomal oxidizing systems produce reactive metabolites of CCl<sub>4</sub> such as trichloromethyl radical (CCl<sub>3</sub>) or trichloroperoxy radical (CCl<sub>3</sub> O<sup>•</sup><sub>3</sub>). These free radicals cause lipid peroxidation which produces hepatocellular damage and enhances production of fibrotic tissue (Kotamballi et al., 2002; Marotta et al., 2003; Ulican et al., 2003). When liver cell plasma membrane is damaged, a variety of enzymes normally located in the cytosol are released into the blood stream. The enhanced activities of ALT, AST and ALP observed in CCl<sub>4</sub>-treated rats in this study corresponded to the extensive liver damage induced by toxin (Figure 1). The tendency of these enzymes to return

towards a near normal level in groups III, IV and V is a clear manifestation of antihepatotoxic effect of *C. intybus* extract (Figure 1).

In this study significant rise in concentration of TB in group II, but not in other groups treated with *C. intybus* offered hepatoprotection as evidenced by the inhibition of the rise in TB levels (Table 1). Hypoalbuminemia and decline in TP content can be deemed as a useful index of severity of hepatocellular damage. The lowered levels of TP and Alb recorded in the serum as well as in the liver of CCl<sub>4</sub>-treated rats reveal the severity of hepatopathy (Aniya et al., 2005). In present study TP and Alb concentrations were very low in rats treated with CCl<sub>4</sub>. In groups III, IV and V these factors significantly increased when compared to the CCl<sub>4</sub>-treated group and the values were closer to those of the control (Table 1). A comparative histopathological study of liver from different groups (Figure 2) demonstrated the protective action of the crude extract against liver damage. In conclusion, the results of the present study suggest that the *C. intybus* extract possess hepatoprotective activity against CCl<sub>4</sub> intoxication rats. According to these results it can be suggested that hepatoprotective action of *C. intybus* may be due to its membrane stabilizing effect on hepatic cells by the antioxidant effect of extract. Further elucidation of structure of active component(s) is under progress in the laboratory.

## ACKNOWLEDGEMENTS

The authors wish to thank the research council of the Yasuj University of Medical Sciences for providing the financial support for this study.

## REFERENCES

- Ahmed B, Al-Howiring TA, Siddiqui AB (2003). Antihepatotoxic activity of seeds of *Cichorium intybus*. J. Ethnopharmacol. 87: 237-240.
- Amin GR (1991). Traditional Herbal Medicine in Iran, Vol:1 (in Persian), Ministry for Health Vice Chancellor for Research and Technology Publishers, Tehran. p. 53
- Aniya Y, Koyama T, Miyagi C, Miyahira M, Inomata C, Kinoshita S, Ichiba T (2005). Free radical scavenging and hepatoprotective actions of the medicinal herb, *Crassocephalum crepidioides* from the Okinawa Islands. Biol. Pharm. Bull. 28: 19-23.
- Hewawasam RP, Jayatilaka KAPW, Pathirana C, Mudduwa LKB (2004). Hepatoprotective effect of *Epaltes divaricata* extract on carbon tetrachloride induced hepatotoxicity in mice. Indian J. Med. Res. 120: 30-34.
- Jindal MN, Patel VK, Patel NB (1975). Pharmacological actions of aqueous and alcoholic extracts of roots of *Cichorium intybus*. Indian J. Pharmacol. 7: 24-33.
- Mankani KL, Krishna V, Manjunatha BK, Vidya SM, Jagadeesh SDJ, Manohara YN, Raheman AU, Avinash KR (2005) Evaluation of Hepatoprotective activity of stem bark of *Pterocarpus marsupium* Roxb. Indian J. Pharmacol. 37(3): 165-168.
- Marotta F, Shield YR, Bamba T, Naito Y, Minelli E, Yoshioka M (2003). Hepatoprotective effect of *Curcumin absinthium* compound in experimental server liver injury. Chinese J. Diges. Disease 4: 122-127.
- Murthy KNC, Jayaprakasha GK, Singh RP (2002). Studies on antioxidant activity of Pomegranate (*Punica granatum*) peel extract using in vivo models. J. Agric. Food Chem. 50: 4791-4795.
- Nayeemunnisa, Rani MK (2003). Cardioprotective effects of *Cichorium intybus* in ageing myocardium of albino rats. Curr. Sci. 84: 941-943.
- Porchezian E, Ansari SH (2005). Hepatoprotective effect of *Abutilon indicum* on experimental liver damage in rats. Phytomed. 12: 62-64.
- Pushparaj PN, Low HK, Manikandan J, Tan BKH, Tan CH (2007). Anti-diabetic effects of *Cichorium intybus* in streptozotocin-induced diabetic rats. J. Ethnopharmacol. 111:430-434.
- Sadeghi H, Yazdanparast R (2003). Effect of *Dendrostellera lessertii* on the intracellular alkaline phosphatase activity of four human cancer cell lines. J. Ethnopharmacol. 86: 11-14.
- Scott Luper ND (1998). A review of plants used in the treatment of liver disease: part1. Altern. Med. Rev. 3: 410-421.
- Sethuraman MG, Lalitha KG, Raj Kapoor B (2003). Hepatoprotective activity of *Sarcostemma brevistigma* against carbon tetrachloride-induced hepatic damage in rats. Curr. Sci. 84: 1186-1187.
- Srivastava A, Shivanandappa T (2006). Hepatoprotective effect of aqueous extract of the roots of *Decalepis hamiltonii* against ethanol – induced oxidative stress in rats. Hepatol. Res. 35: 267-275.
- Ulican O, Greksak M, Vancova O, Zlatos L, Galbavy S, Bozek P, Nakano M (2003). Hepatoprotective effect of Rooibos tea (*Aspalathus linearis*) on CCl<sub>4</sub> –induced liver damage in rats. Physiol. Res. 52: 461-466.
- Venukumar MR, Latha MS (2002). Hepatoprotective effect of the methanolic extract *Curculigo orchioides* in CCl<sub>4</sub>-treated male rats. Indian J. Pharmacol. 34: 269-275.
- Zafar R, Mujahid AS (1998). Antihepatotoxic effects of root and root callus extracts of *Cichorium intybus*. J. Ethnopharmacol. 63: 227-231.