

Short Communication

Histological observations of 24 hours administration of the extract of *Sorghum bicolor* on albino rats

¹Owolagba G.K., ²Avwioro O.H., ³Oduola T., ⁴Adeosun O.H., ²Enaowho T.M., ²Wilson J.I.,
³Ajumobi KO

¹Department of Histopathology, Ahmadu Bello University Teaching Hospital, Zaria, Nigeria.

²Department of Anatomy and Cell Biology, Delta State University, Abraka, Nigeria.

³Special Investigations Laboratory, Department of Haematology, Obafemi Awolowo University Teaching Hospital, Ile Ife, Nigeria.

⁴Department of Chemical Pathology, Obafemi Awolowo University Teaching Hospital, Ile Ife, Nigeria.

⁵Department of Histopathology, Federal Medical Centre, Ido Ekiti, Nigeria.

Accepted 14 May, 2021

The histological effects of oral administration of the alcoholic extract of *Sorghum bicolor* on albino rats were investigated. The alcoholic extract was dried and resuspended in distilled water and the following quantities were administered orally to the albino rats per kg body weight: 10, 100, 1000, 1500, 2000 and 2900 mg while normal saline solution served as control. The rats were dissected after 24 h. Tissues from the heart, liver, and kidney were histologically processed and stained with haematoxylin and eosin and the sections subjected to histopathological examination. Results showed that albino rats fed with *S. bicolor* extracts in doses above 2000 mg/kg body weight showed observable changes of varying degrees of congestion in the heart, liver and kidney according to the concentration of doses injected. Lethal dose of 2900 mg/kg was observed arising from periportal inflammation and vacuolation of the hepatocytes.

Key words: *Sorghum bicolor* extract, lethal dose, albino rats, histopathology.

INTRODUCTION

Sorghum bicolor also called guinea corn is a short – term perennial plant. The leaves are broad and coarse, similar in shape to those of corn but shorter and wider. Their blades are glabrous and waxy; sheaths encircle culms and have overlapping margins; panicle erect, sometimes curved, usually compact in most grains. Sorghum is used largely for forage in the US; it is very important in the world's human diet, with over 300 million people dependent on it. The leaves are also of some local importance. For example, it is widely used among West Africans to make local antibiotic syrup (Bukantis, 1980). Stalks are used as animal feed. *Sorghum*, with large juicy stems containing as much as 10% sucrose, is used in the manufacture of syrup. The seeds are used as food, in brewing local beer, the corn malt and cornmeal are fermented to make a sour mash, the pith is eaten, and the sweet culms chewed (Watt and Breyer-brandwijk, 1962).

In India, the plant is considered anti helminthic and as an insecticide, and in South Africa, in combination with *Erigeron Canadensis* it is used for eczema (Watt and Breyer-Brandwijk, 1962). Ogwumike (2002) in a haematological study conducted on albino rats supported the traditional use of *S. bicolor* as a remedy for anemia. In Africa, the dye extracted from *S. bicolor* is used in coloring leather, clothes, and calabashes and as a body pigment (Sereme et al., 1993). Recently, Avwioro et al. (2006) used crude ethanolic extract of *S. bicolor* to stain red blood cells, collagen and muscle fibers. In their study, the alkaline mixtures did not stain any of the tissues used but the acidic and natural alcoholic mixtures stained collagen fibers, muscles and red blood cells in shades of pinkish-yellow. Elution of the stain from the stained sections confirmed the dye to be apigeninidin. Before any new dye can be used, its biosafety must be determined. The aim of the study therefore was to determine the safety of the histological dye extracted from *S. bicolor* within 24 h of oral ingestion.

MATERIALS AND METHODS

Collection of materials

Male and female albino rats of various sizes were obtained from the animal house of the Department of Biological Sciences, Ahmadu Bello University, Zaria, Nigeria. The leaf sheaths of *S. bicolor* plant were collected fresh and identified at the herbarium of Ahmadu Bello University, Zaria, Nigeria. The leaf sheaths were washed several times in running tap water and finally in three rinses of distilled water. The leaf sheaths of the plant were cut into tiny bits of about 0.5 cm in length, air dried for two weeks and subsequently dried to completion on a hot air oven for 48 h at 60°C. They were milled with the use of ceramic mortar and pestles and filtered with a sieve of diameter 0.6 mm to remove coarse and hard materials. The filtrate was weighed and kept in a cool dry place in readiness for extraction.

Extraction and Preparation of Extract

200 g of the filtrate was weighed into a conical flask and completely soaked in 1200 ml of 70% ethanol with intermittent agitation at 60°C for 24 h. The mixture was filtered using a No 1 Whatman filter paper. The sediment was suspended in 70% ethanol and washed four times at 60°C for three hours each. The filtrates were bulked and concentrated in vacuo at 70°C to obtain a very fine dry mass of the extract. The dry mass was resuspended in distilled water and 2 ml each was administered orally to seven groups of rats, two in a group in doses of 10, 100 and 1000 1500, 2000, 2500 and 2900 mg/kg body weight over a period of 2 h. Another group of rats served as the controls as they received equivalent quantity of normal saline. They were all placed under investigation for 24 h after which they were sacrificed.

Tissue processing for histopathology

Tissues were collected from the kidney, liver and heart and fixed immediately in 10% buffered formalin for 24 h. Tissues were cut into 3x3x2 mm thickness and processed by the paraffin wax method using the Leica automatic tissue processor RT 1020 by dehydrating through ascending grades of alcohol for 2h each in 70, 90, 95%, two changes of absolute alcohol, cleared in two changes of xylene for 2 h each and infiltrated in 2 changes of paraffin wax for 2 h each. The tissues were subsequently embedded in paraffin wax using the Leica 1160 embedding machine and sectioned with the Leica RT 2110 rotary microtome at 4 µ m thickness. The sections were floated out on a Gallenkamp water bath at 45°C and dried on a hot plate at 60°C for 30 min. The sections were stained with Mayer's haematoxylin and eosin and examined under the light microscope for general tissue structure.

RESULTS

Histology of the liver

The control sections were normal. Sections from albino rats that received oral administration of 10 to 1500 mg of extract *S. bicolor* were also normal. There was mild to moderate and severe congestion in the blood vessels of rats that received 2000, 2500 and 2900 mg of *S. bicolor* respectively (Plate 1). There was also periportal inflammation and mild vacuolation of the hepatocytes in

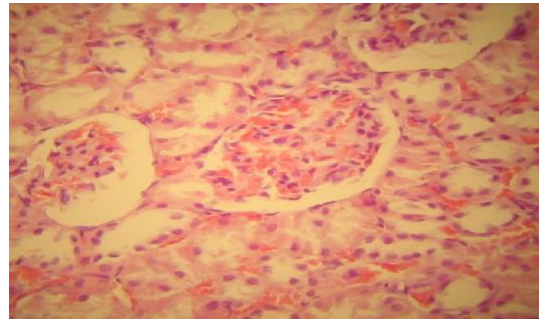


Plate 1. (H&E X400) Section of kidney fed with 2900 mg/kg *S. bicolor*

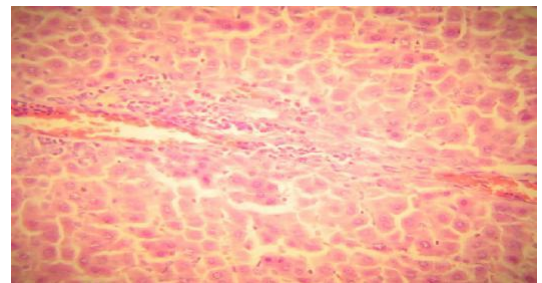


Plate 2. (H&E X400) Section of liver fed with 2900 mg/kg *S. bicolor* extract.

the latter. Focal bridging fibrosis was also observed in doses above 2500 mg per day.

Histology of the kidney

The control sections were normal. Sections from albino rats that received oral administration of 10 to 1500 mg of *S. bicolor* were also normal. There was mild to moderate and severe congestion in the blood vessels of rats that received 2000, 2500 and 2900 mg of extract of *S. bicolor* respectively. There was mild haemorrhage in the glomeruli and few casts in the tubules in sections of rats fed with doses above 2000 mg/kg (Plate 2).

Histology of the heart

The control sections were normal. Sections from albino rats that received oral administration of 10 to 1500 mg of extract of *S. bicolor* were also normal. There was mild to moderate and severe congestion in the blood vessels of the albino rats that received 2000, 2500 and 2900 mg of *S. bicolor* respectively (Plate 3).

DISCUSSION

Successful histological staining technique is used for the distinction of tissue components, but it is also important

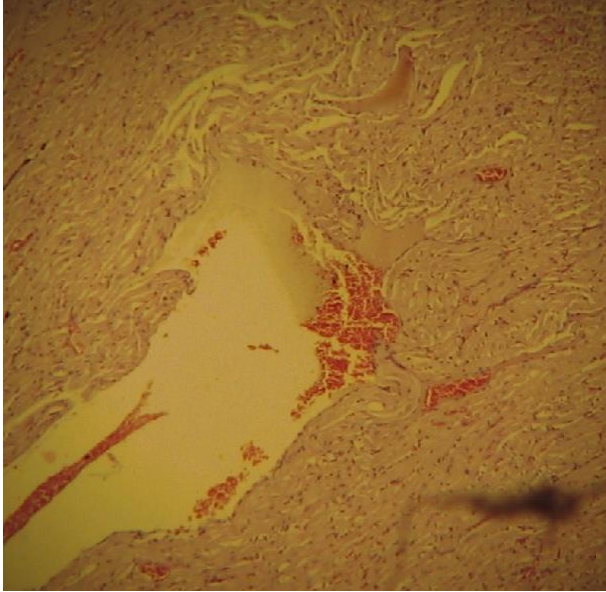


Plate 3. (H&E X400) Section of heart fed with 2900 mg/kg *S. bicolor* extract

histologist. The potential of toxicity depends on the dose and the conditions under which a person is exposed to the substance (Sidell, 1996). Although, the alcoholic extract of *S. bicolor* had been used as a histological dye (Avwioro et al., 2006) and for coloring leather, clothes, calabashes and as a body pigment (Sereme et al., 1993), the safety of the dye to human health has not been determined. Traditionally, the plant has also been used as forage in the United States of America (Bukantis, 1980) for a very long time and no adverse reaction has been reported about the use of the plant. Ogwumike (2002) has also used *S. bicolor* as a remedy for anaemia and did not report any hazard to health in the albino rats. Although *S. bicolor* has been used extensively for the treatment of diseases and as forage, its use as a new histological dye for collagen fibres and muscle fibres must pass certain biosafety conditions before it can be accepted and used without fear by scientists. This is because some dyes have been reported to have carcinogenic effects (Sewekow, 1988) and surprisingly many of such cases were reported after prolonged usage when irreparable damage had been done to the body. For instance dyes containing benzidine are known to cause bowel cancer. During the 24 h oral administration of *S. bicolor* extract, the albino rats that received more than 2500 mg/kg died as a result of congestion and in higher doses as a result of inflammation. This study could not find any immediate adverse reaction as a result of the ingestion of *S. bicolor* below 1500 mg/kg on albino rats within 24 h of administration of the extract. Since this is an acute study, the results of prolonged study may be different from this. The LD₅₀ could not be determined because the LD₅₀ procedure has been criticized exten-

sively owing to the large number of animals which must be sacrificed during the experiment.

REFERENCES

- Avwioro OH, Aloamaka CP, Olabampe OB, Oduola T (2006). Collagen and muscle stain obtained from *Sorghum bicolor*. *Scand J Clin Lab Invest* 66: 161–168
- Bukantis R (1980). Energy inputs in sorghum production. In: Pimentel D. editor. *Handbook of energy utilization in agriculture*. Boca Raton, Florida: CRC Press, Inc.; pp 103–108.
- Ogwumike O O (2002). Hemopoietic effect of aqueous extract of the leaf sheath of *Sorghum bicolor* in Albino rats African J. Biomedical Resh. 5:69 – 71
- Sereme A, Koudabonafos M, Nacro M (1993). Phenolic compounds in sorghum-caudatum tissues during plant development. *Bioenergy* 4:69–71.
- Sidell F (1996). *Chemical agent terrorism*, Med. Org.
- Sewkow, U. (1988). Natural dyes -an alternative to synthetic dyes. *Melliand Textilber* 69 (4): 145-48.
- Watt JM, Brayer-Brandwijk MG (1962). *The Medical and Poisonous Plants of Southern and Eastern Africa*. 2nd edition. E & S Livingstone Ltd. Edinburgh and London.