

Full Length Research Paper

## Hypoglycemic effect of *Basella rubra* in streptozotocin – induced diabetic albino rats

A. Nirmala<sup>1\*</sup>, S. Saroja<sup>2</sup>, H. R. Vasanthi<sup>3</sup> and G. Lalitha<sup>1</sup>

<sup>1</sup>Department of Biotechnology, Aarupadai Veedu Institute of Technology, Paiyanoor, Tamil Nadu, India.

<sup>2</sup>Department of Biochemistry, Avinashilingam Institute for Home Science and Higher Education for Women, Coimbatore, Tamil Nadu, India.

<sup>3</sup>Herbal and Indian Medicine Research Laboratory, Department of Biochemistry, Sri Ramachandra University, Porur, Chennai-16, India.

Accepted 14 July, 2020

Great efforts are ongoing in understanding and management of diabetes, the disease and disease-related complications are increasingly unabated. In spite of the presence of known antidiabetic medicine in the pharmaceutical market, remedies from medicinal plants are used with success to treat this disease. In the present investigation an attempt is made to study the beneficial effects of *Basella rubra* in streptozotocin-induced diabetic rats and validate its traditional claim. The diabetes-induced rats were fed with *Basella rubra* (400 mg/100 gm body weight orally through a gavage), when tested after ingestion the fasting blood glucose levels were remarkably reduced to normal and liver glycogen content was remarkably increased. In pancreatic sections of diabetic rats fed with *B. rubra*, the islets were normal comparable to diabetic controlled rats (insulinitis was observed). In liver, the changes caused after induction of diabetes was global microvesicular steatosis. The portal tracts appeared normal and central veins appeared congested, which was brought back to normal after feeding with *B. rubra*. While, in the kidney sections, of diabetic control rats and diabetic rats fed with *B. rubra* no histopathological changes were noticed. The results demonstrate that the leaf pulp of *B. rubra* possesses a strong hypoglycemic effect in streptozotocin-induced diabetic rats, thus supporting its traditional use in diabetes mellitus control.

**Key words:** *Basella rubra* (*B. rubra*), hypoglycemic effect, pancreas, streptozotocin-induced diabetic rats, blood glucose.

### INTRODUCTION

Diabetes mellitus is a complex and a multifarious group of disorders that disturbs the metabolism of carbohydrates, fats and proteins. It results from shortage or lack of insulin secretion or reduced sensitivity of the tissue to insulin. Several drugs such as biguanides and sulfonylureas are currently available to reduce hyperglycemia in diabetes mellitus (Mutalik et al., 2003). These drugs have side effect and thus search for new drug/compound is essential to overcome the diabetic problems (Noor et al., 2008). Management of diabetes without any side effect is still a challenge to medical community. Therefore, it is

prudent to look for options in alternative medicine/herbal for diabetes as well. Although, herbal medicines have long been used effectively in treating disease in Asian communities and throughout the world, yet the mechanism of most of the herbals used has not been defined (Baily and Day, 1989). It has been attributed that the antihyperglycemic effect of these plants is due to their ability to restore the function of pancreatic tissues by causing an increase in insulin output or inhibit the intestinal absorption of glucose or facilitation of metabolites in insulin-dependent process. Hence, treatment with herbal drugs has an effect on protecting  $\beta$ -cells and smoothing out fluctuation in glucose levels (Jia, 2003; Elder, 2004). Most of the plants have been found to contain substance like glycosides, alkaloids, terpenoids, flavonoids etc, that are frequently impli-

\*Corresponding author. E-mail: [nimmi\\_aruna@yahoo.com](mailto:nimmi_aruna@yahoo.com). Tel.: 9841681587.

cated as having on the specific mode of action of these plants drug or herbal formulation used for treating diabetes (Loew and kaszkin, 2002). The ethnobotanical information reports state that about 800 plants may possess antidiabetic potential (Aguilara et al., 1998). Based on the WHO recommendations hypoglycemic agents of plants origin used in traditional medicine are important (WHO, 1980). Plant drugs (Halberstein, 2005) and herbal formulation (Mitra et al., 1996) are frequently considered to be less toxic and more free from side effects than the synthetic ones.

*Basella rubra* known as Malabar spinach is also known as cyclone spinach. It belongs to *Basellaceae* family. It is a climbing perennial plant. Malabar spinach has thick tender stems and the leaves are almost circular to ovate, alternate and short petioled. They are thick, rugose, succulent and colored from green to purple. The leaves are used in catarrhal affection and to hasten suppuration. Decoction of the root relieves bilious vomiting (Nadkarani, 1976). In general, spinach leaves contain several active components including flavonoids exhibit antioxidative, antiproliferative and anti-inflammatory properties in biological system. Spinach extracts have been demonstrated to exert numerous beneficial effects such as chemo and central nervous system protection, anticancer and antiaging function (Lomintski et al., 2003).

However, available literature shows that no experimental work has been carried out to verify the claims on the anti-diabetic effect of *B. rubra*. Therefore, it was considered worthwhile to undertake this study to evaluate the anti-diabetic activity of *B. rubra* in streptozotocin-induced diabetic rats.

## MATERIALS AND METHODS

### Plant materials

*B. rubra* plant was collected from the village area (Dindigul district) and raised in the university campus under normal climatic conditions (35 - 37°C). The plant was identified and authenticated (No.BSI/SC/5/21/04-05/Tech.367) from Botanical Survey of India (BSA), Tamil Nadu Agriculture University (TNAU) Coimbatore. Fresh leaves were collected for the study whenever required.

### Preparation of the plant sample

Fresh leaves of *B. rubra* (400 mg) ground with 10 ml water in a mortar and pestle. The grounded material was utilized for the experiment.

### Animals and treatment

Male albino rats were selected for the study. They were of the same age and weight (150 – 200 gm). The rats were housed in polycarbonated clean cages under a 12 /12 h normal light/dark cycle. The animals were fed with standard diet and water *ad libitum*. After keeping in the laboratory condition for a week for acclimatization the experiment was initiated.

A total of 24 rats were categorized into 4 groups, each group consisting of 6 rats.

Group I: Was normal healthy control.

Group II: Diabetic control, diabetes was induced in rats after 18 h fasting by intraperitoneal administration of streptozotocin (60 mg/kg body weight dissolved in 10 mM citrate buffer pH 4.5) (Archana et al., 2001). STZ injected animals exhibited massive glycosuria and hyperglycemia within few days. Diabetes was confirmed in STZ rats by measuring the fasting blood glucose concentration. A blood glucose level of 200 mg/dl was considered a diabetic.

Group III: Rats are non diabetic rats treated with *B. rubra*.

Group IV: Diabetic rats administered with *B. rubra*.

The *B. rubra* paste (400 mg/100 gm body weight) was orally gaged to group III and IV daily for 30 days. After 30 days of treatment, the blood samples were collected after overnight fasting and it was used for separating the serum for analyzing the biochemical parameters.

### Biochemical parameters

Glucose is an indispensable energy supplying substrate, which supports cellular function and is an important marker in diabetes. So in the present study blood glucose was estimated in control as well as in diabetic animals by the method of Raghuramulu et al. (1983). In this method, 0.2 ml of sample was added to 1.8 ml of distilled water, mixed well. To 0.5 ml of the made up sample 5.0 ml of Orthotoluidine reagent was added and kept in a boiling water bath for 10 min. The absorbance was measured at 620 nm after cooling. Similarly, the liver glycogen was estimated by the method of Good et al. (1933). The liver was taken out rapidly from the animal and the excess blood was removed by blotting between folds of filter paper and weighed, approximately 0.1 g of the tissue. The minced liver was then used for the analyses per the procedure.

### Statistical analyses

Statistical analysis was performed by one way analysis of variance (ANOVA) followed by Duncans Multiple Range Tests (DMRT). All values were expressed as mean with their Standard Deviation (SD) P values < 0.05 were considered as significant.

### The histological study

After blood sampling for the biochemical analyses, the animals were sacrificed, quickly dissected and small slices of liver, kidney and pancreases were taken and fixed in 10% formalin. The specimens were dehydrated in ascending grades of ethanol, cleared in xylene and embedded in paraffin wax. Sections of 6 m in thick-ness were prepared and stained with haematoxylin and eosin (Drury and Wallington, 1980) and subjected to microscopical examination.

## RESULT

Streptozotocin causes selective destruction of cells of islets of pancreas and brings an increase in blood glucose levels. It is evident from the present investigation that streptozotocin administration at the dose of 60 mg/kg albino rats. Table 1 shows that the *B. rubra* exhibit anti-diabetic property in streptozotocin- induced diabetic rats as evident from changes in serum glucose level. There was an increased level of blood glucose in STZ -induced animals (diabetic control) which was drastically reduced by supplementing with *B. rubra*. Thus, it is interesting to

**Table 1.** Blood glucose level in experimental rats.

Groups	Treatment	Glucose mg/dl
Group I	Non-diabetic control	80.0 ± 3.65 <sup>a</sup>
Group II	Diabetic control	252.0 ± 4.16 <sup>c</sup>
Group III	Non-diabetic + <i>B. rubra</i>	82.0 ± 4.76 <sup>a</sup>
Group IV	Diabetic + <i>B. rubra</i>	110.1 ± 3.93 <sup>b</sup>

Values are mean ± SD values.

With different superscripts (a, b) statistically significant compared with diabetic control (P < 0.05).

**Table 2.** Liver glycogen content in experimental rats.

Groups	Treatment	Glucose mg/dl
Group I	Non-diabetic control	53.3 ± 2.01 <sup>a</sup>
Group II	Diabetic control	38.6 ± 2.60 <sup>b</sup>
Group III	Non-diabetic + <i>B. rubra</i>	54.7 ± 2.15 <sup>a</sup>
Group IV	Diabetic + <i>B. rubra</i>	52.0 ± 2.58 <sup>a</sup>

Values are mean ± SD values.

With different superscript (a) statistically significant compared with diabetic (b) control (P < 0.05).

note that common leafy greens could control the blood glucose to normal.

Table 2 shows that there was marked reduction in liver glycogen levels in streptozotocin-induced diabetic animals. These herbal extract treatments remarkably increase the glycogen content in diabetic rats when compared with diabetic control.

### Liver histology

Group I rats showed that, the hepatocytes are seen as cords radiating from the central veins. The portal tracts were composed of portal vein radicle, hepatic artery radicle and bile duct radicle. The central veins appeared normal. In case of group II diabetic rats, the hepatocytes showed the global microvesicular steatosis. The portal tracts appeared normal and the central veins appeared congested –Global microvesicular steatosis. In the non-diabetic rats treated with *B. rubra* the hepatocytes, portal tracts and central veins appeared normal. No pathological changes were observed. In group IV [diabetic rats+ *B. rubra*], the hepatocytes portal tracts and central veins appear normal. No steatosis was observed (Plate 1).

### Pancreas histology

Histology of the islets of Langerhans of normal control rats showed predominant exocrine pancreatic tissue composed of acini with draining ductules. The endocrine component was found as scattered nodules within the substance of the exocrine pancreas exhibiting no pathological changes. However, in the group II diabetic animals,

the sections revealed predominant exocrine pancreatic tissue composed of acini with draining ductules. The endocrine component was found as scattered nodules within the substance of the exocrine pancreas relating to focal mild infiltration by mononuclear cell. Microscopical examination of non-diabetic animals treated with *B. rubra* depicts the predominant exocrine pancreatic tissue composed of acini with draining ductules. The endocrine component was found as scattered nodules within the substance of the exocrine pancreas revealing absence of pathological changes. However, in group IV animals, the endocrine component was found as scattered nodules within the substance of the exocrine pancreas showing no signs of insulinitis as observed in group II (Plate 2).

### Kidney histology

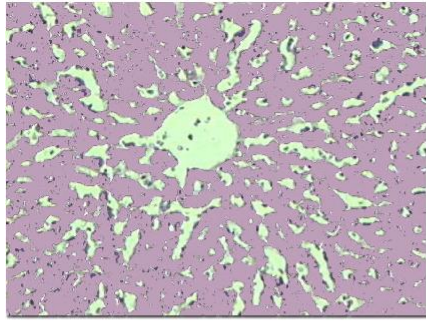
Kidney section study in all the groups (Groups I, II, III and IV) showed that the glomeruli, tubules, blood vessels and interstitium appear normal. No pathological changes were observed. (Plate 3)

## DISCUSSION

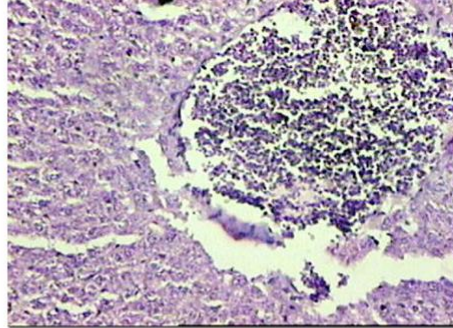
At present the treatment of diabetes mainly involves a sustained reduction in hyperglycemia by the use of biguanides, thiazolidinediones, sulfonylureas and D- phenylalanine derivatives, meglitinides and alpha glucoside inhibitors in addition to insulin. However, due to untoward side effects the efficacy of these compounds are debatable and there is a demand for new compounds for the treatment of diabetes (Jackson and Bressler, 1981; Thirunavukkarasu et al., 2003). Hence, plants have been suggested as a rich, as yet unexplored source of potentially useful antidiabetic drugs.

Spinach commonly taken, it contains powerful water soluble, natural antioxidant mixture (NAO) which specially inhibits the lipoxygenase enzymes. The antioxidative activity of NAO has been compared to that of other known antioxidants and found to be superior *in vitro* and *in vivo* to that of green tea, N-acetyl cysteine (NAC), butylated hydroxytoluene (BHT) and vitamin E. NAO has been found to be non-mutagenic in experimental models such as skin and prostate cancer and has not shown any target –organ toxicity or side effects (Lomnitski et al., 2003). Similarly, the antioxidant activity of the novel antioxidant glucurinated flavonoid (GF) were also isolated and characterized from spinach leaves. In addition, the direct free radical scavenging properties of the purified component GF were studied using the Electron spin resonance technique. The results obtained from the study indicate that the natural antioxidants derived from spinach may directly affect the scavenging of Reactive Oxygen Species (ROS) and as a consequence may be considered as an effective source for combating oxidative damages (Bergman et al., 2003).

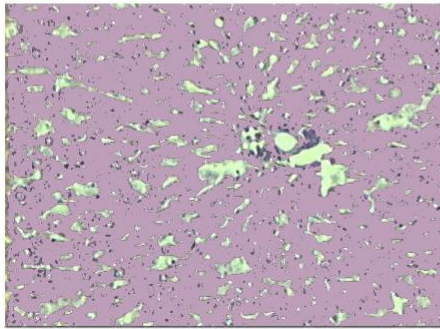
Oxidative stress, through the production of ROS, has



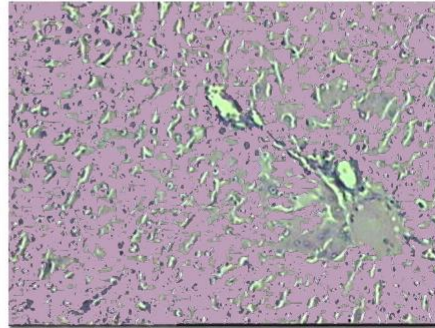
Non diabetic control



Diabetic control

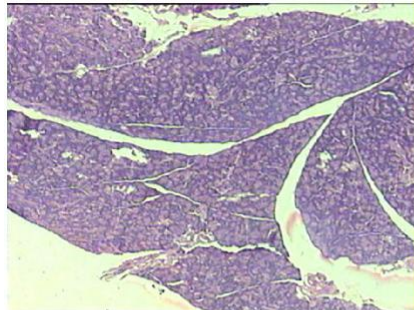


Non diabetic + *Basella rubra*

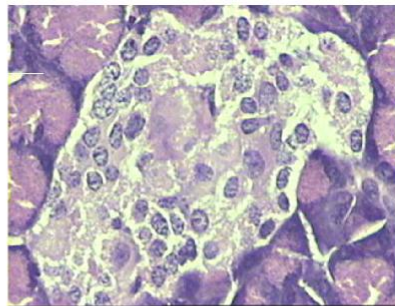


Diabetic + *Basella rubra*

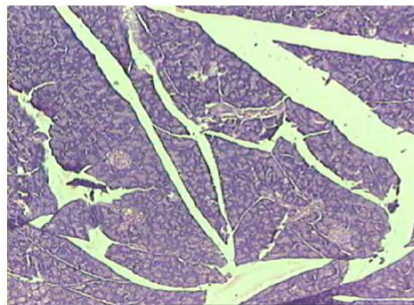
**Plate 1.** Liver sections of the rat.



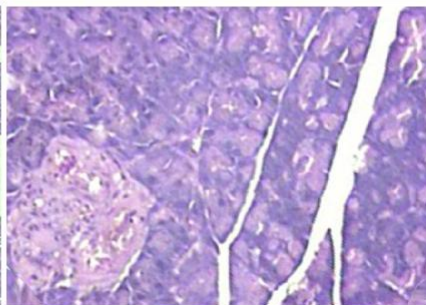
Non diabetic control



Diabetic control

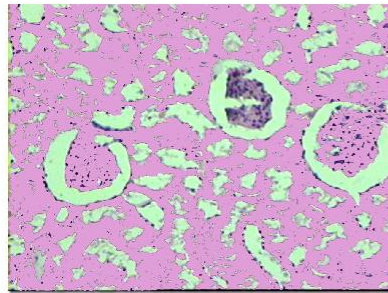


Non diabetic + *Basella rubra*

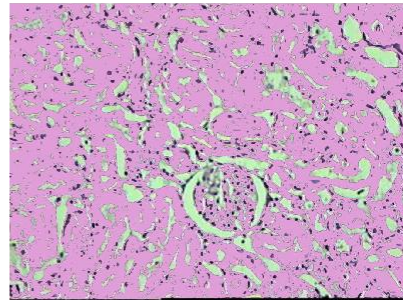


Diabetic + *Basella rubra*

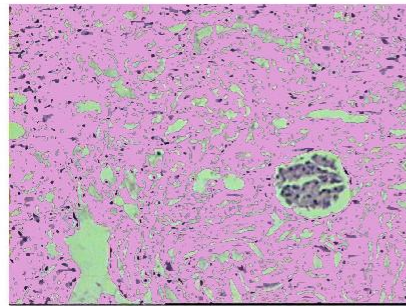
**Plate 2.** Pancreas sections of the rats



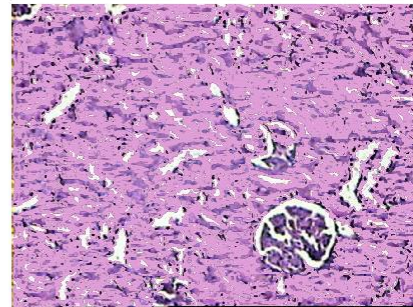
Non diabetic control



Diabetic control



Non diabetic + *Basella rubra*



Diabetic + *Basella rubra*

Plate 3. Kidney sections of the rats.

been proposed as the root cause underlying the development of insulin resistance,  $\beta$ -cell dysfunction, impaired glucose tolerance and type 2 diabetes mellitus (T2DM). It has also been implicated in the progression of long-term diabetes complications including microvascular and macrovascular dysfunction (Wright et al., 2006). *B. rubra* in the present study might have exhibited anti-diabetic activity probably mitigating the oxidative stress in diabetic condition.

In this present study blood glucose levels were normal in healthy rats fed with *B. rubra*. The behavior of normal rats fed with *B. rubra* appeared normal and no mortality was observed, indicating that there was no acute toxic effects of *B. rubra* feeding. Besides, in diabetic rats treated with *B. rubra* there was a significant blood glucose reduction and increased glycogen content. Our results are corroborative with Zhang (2003) and Kiho et al. (1992) who reported that treatment of alloxan-induced diabetic rats with *Rehmannia glutinosa* oligosaccharide for 15 days resulted in a significant decrease in blood glucose level and increase in hepatic glycogen content. There may be 2 possible explanations for the observed results. *B. rubra* might have exerted its effect by preventing the death of beta cells and/or may have helped in the rejuvenation/recovery of partially destroyed beta cells like *Momordica charantia* (Ahmed et al., 1998).

During diabetes liver shows decrease in weight due to enhanced catabolic process such as glycogenolysis, lipolysis and proteolysis, which is the outcome of lack of

insulin and or cellular glucose in liver cells. There is, however, an increase in the weight of the kidney due to glucose over utilization and subsequent enhancement in glycogen synthesis, lipogenesis and protein synthesis (Meyer et al., 1998). These changes may lead to serious microvascular renal complications, which involve a series of metabolic changes in the pathogenesis of diabetic nephropathy (Raju et al., 2001). In our study, treatment with *B. rubra* significantly prevented the alteration in liver pathology to normalcy. Abou E1-Soud et al. (2007) who has reported that diabetic rats with fenugreek alkaloids significantly prevented the alteration in liver and kidney weight and pathology with return to their normal texture.

In our study, the most significant finding observed in aqueous leaves extract of *B. rubra* treated diabetic rats showed the predominant exocrine pancreatic tissue composed of acini with draining ductules. The endocrine component was found as scattered nodules within the substance of the exocrine pancreas. No insulinitis were observed when compared to diabetic controlled rats. Ayesha noor et al. (2008) also reported that pancreas and liver sections of diabetic rats fed with *Aloe vera* were normal when compared with diabetic control rats.

In a study reported by Bolkent et al. (2004) in the neonatal STZ- (100 mg /kg) induced type –II diabetes alteration in the structural integrity of the apical membrane of proximal tubules of the kidney tissue in the diabetes rats were observed. In our study there were no noticeable changes in the histology of kidney.

## Conclusion

The result of the present study showed that *B. rubra* brings back the blood glucose and body weight to normal in diabetes-induced rats. After treatment with *B. rubra*, liver section of diabetic rats hepatocytes, portal tracts and central veins appeared normal. In the pancreas no insulinitis was observed. From the above results it is shown that it has (*B. rubra*) hypoglycemic activity. Hypoglycemic action of the herbal plant (*B. rubra*) in diabetic rats may be possible through the insulinomimetic action or by other mechanism such as stimulation of glucose uptake by peripheral tissue, inhibition of endogenous glucose production, or activation of gluconeogenesis in liver and muscle. It may prevent the hepatic injury and pancreas and suppressing the oxidative stress associated with diabetes. Although the exact chemical compounds responsible for the hypoglycemic effects of *B. rubra* still remain speculative, experimental evidence obtained from this study indicates that *B. rubra* possess hypoglycemic property, which also is confirmed by histopathological examination.

## REFERENCES

- Abou El-Soud NH, Khalil MY, Hussein JS, Oraby FSH, Hussein Farrag AR (2007). Antidiabetic effect of fenugreek alkaloid extract in streptozotocin induced hyperglycemic rats. *J. Appl. Sci. Res.* 3(10): 1073-1083.
- Aguliera FJA, Ramos RR, Gutierrez SP, Contreras AA, Weber CCC, Saenz JLF (1998). Study of the antihyperglycemic effect of plants used as antidiabetes. *J. Ethnopharmacol.* 61: 101-110.
- Archana S, Rashmi N, Khemani LD (2001). Hypoglycemic effect of Hibiscus rosasinensis L. leaf extract in glucose and streptozotocin induced hypoglycemic rats. *Indian J. Ex. Biol.* 39: 284-286.
- Ahmed I, Adghate E, Sharma AK, Singh PDJ (1998). Effects of Momardica charantia fruit juice on islet morphology in the pancreas of the streptozotocin-diabetic rat. *Dia. Res. Clin. Pract.* 40: 145-151.
- Ayesha N, Gunasekaran S, Soosai MA, Vijayalakshmi MA (2008). Antidiabetic activity of *Aloe vera* and histology of organs in extracts on kidney in type II diabetic rat models. *Indian J. Ex. Biol.* 42: 48-52.
- Baily CJ, Day C (1989). Traditional plants medicines as treatments for diabetes. *Diabetes Care* pp.553-564.
- Bergman M, Perelman A, Dubinsky Z, Grossman S (2003). Scavenging of reactive oxygen species by a novel glucurinated flavonoid antioxidant isolated and purified from spinach. *Phytochem.* 62(5): 753-62.
- Drury RA, Wallington EAC (1980). Coreleton's Histological technique 4<sup>th</sup> edition. Oxford. Oxford University Press.
- Elder C (2004). Ayurveda for diabetes mellitus: a review of the biomedical literature. *Alter Ther. Health Med.* 10: 44-50.
- Good CA, Krames H, Somogy M (1933). Chemical procedure for analysis of polysaccharides. *Meth. Enzymol.* 8: 34.
- Halberstein RA (2005). Medicinal plants: historical and cross-cultural usage patterns. *Ann. Epidemiol.* 15: 686-99.
- Jackson JE, Bressler R (1981). Clinical pharmacology of sulphonylurea hypoglycemic agents: Part 1. *Drugs* 22: 211-245.
- Jia W, Gao WY, Xiao PG (2003). Antidiabetic drugs of plants origin used in china: composition, pharmacology and hypoglycemic mechanism. *Zhongguo Zhong Yao Za Zhi* 28: 108-113.
- Kiho T, Watanabe TNK, Ukai S (1992). Hypoglycemic activity of polysaccharide fraction from rhizome of *Rehmannia glutinosa* LIBOSC *F. hueichingensis* HSIAO and the effect of carbohydrate metabolism in normal mouse liver. *Yokugaku zasshi* 112: 393-400.
- Loew D, Kaszkin M (2002). Approaching the problem of bioequivalence of Herbal Medicinal Products. *Phytother Res.* 16: 705-711.
- Lomnitski L, Bergman M, Nyska A, Ben-shaul V, Grossman S (2003). Composition, efficacy and safety of spinach extracts. *Nutr. cancer.* 46(2): 222-31.
- Mutalik S, Sulochana B, Chetana M, Udupa N, Devi VP (2003). Preliminary studies on acute and subacute toxicity of an antidiabetic herbal preparation-Dianex. 41: 316-320.
- Mitra SK, Gopumadhavan S, Muualidhar TS, Anturlikar SD, Sujatha MB (1996). Effect of a herbomineral preparation D-400 in streptozotocin induced diabetic rats. *J. Ethnopharmacol.* 54: 41-46.
- Meyer C, Stumvoll M, Nadkarni VJ, Dostou A, Mitrakou, Gerich J (1998). Abnormal renal and hepatic glucose metabolism in type 2 diabetes mellitus. *J. Clin. Invest.* 102: 619-624.
- Noor A, Gunasekaran S, Manickam AS, Vijayalakshmi MA (2008). Antidiabetic activity of *Aloe vera* and histology of organs in streptozotocin-induced diabetic rats. *Curr. Sci.* 94: 1070-1076.
- Nadkarni KM (1976). *Indian Material Media. Withayurvedic, unanittibbi, siddha, allopathic, homeopathic, naturopathic and home remedies, appendices and indexes, volume 1 & 2.* Bombay popular prakashan PVT, LTD.
- Raghuramulu N, Nair MK, Kalyanasundaram SA (1983). *Manual of laboratory techniques, 1st edition, National Institute of Nutrition, KMR, Hyderabad pp.31-32.*
- Raju J, Gupta D, Rao AR, Yadava PK, Baquer NZ (2001). *Trigonella foenum-graecum* (Fenugreek) seed powder improves glucose homeostasis in alloxan diabetic rats tissues by reversing the altered glycolytic, gluconeogenic and lipogenic enzymes; *Mol. Cell. Biochem.* 224: 45-51.
- Thirunavukkarasu V, Anuradha CV, Viawanathan P (2003). Protective effect of fenugreek (*Trigonella foenum graecum*) seeds in experimental ethanol toxicity. *Phytother. Res.* Aug. 17: 737-743.
- WHO Expert (1980). Committee on Diabetes Mellitus Technical Report Series 646, Geneva and World Health Organization.
- Wright E, Scism-Bacon JL, Glass LC (2006). Oxidative stress in type 2 diabetes: the role of fasting and postprandial glycaemia. *Int. J. Clin. Pract.* 60(3): 308-314.
- Zhang R, Zhou J, Jia Z, Zhang Z, Gu G (2003). Hypoglycemic effect of *Rehmannia glutinosa* oligosaccharide in hyperglycemic and alloxan-induced diabetic rats and its mechanism. *J. Ethnopharmacol.* 90:190