

Research Article

Outcomes of endoscopic interventions for ureterocele in adults: A comprehensive institutional review

G Janardhan Goud*

Department of Urology and Nephrology, Rajendra Institute of Medical Sciences, Ranchi, India

Received: 12-July-2024, Manuscript No. IJUN-24-141607; Editor assigned: 15-July-2024, Pre QC No. IJUN-24-141607 (PQ); Reviewed: 30-July-2024, QC No. IJUN-24-141607; Revised: 12-January-2025, Manuscript No. IJUN-24-141607 (R); Published: 20-January-2025

ABSTRACT

This retrospective study aims to comprehensively examine the epidemiological and clinical aspects of ureterocele in adult patients and to discuss therapeutic modalities. The investigation covers a meticulous analysis of medical records from 11 adult patients treated for ureterocele over a 3-year period (2020-2023) at Mamata Medical College.

Objective: The primary objective of this study is to present a detailed understanding of the epidemiological and clinical characteristics of ureterocele in adults and to discuss various therapeutic modalities employed in managing this condition.

Patients and methods: A rigorous retrospective analysis of medical records was conducted for adult patients diagnosed with ureterocele during the 3-year period from 2020 to 2023 at Mamata Medical College. The parameters under scrutiny encompassed epidemiological factors, clinical manifestations, paraclinical findings, therapeutic interventions and the evolution of the condition.

Results: The cohort consisted of 11 patients, with an average age of 36.3 ± 12 years, comprising six women and five men. The mean time of consultation ranged from 12 to 36 months. Clinical symptoms prompting consultation included atypical back pain (n=3), renal colic (n=2), and pelvic pain (n=2). Diagnostic procedures comprised ultrasound (n=7), intra venous urography (n=5) and CT urography (n=2). Ureterocele was bilateral in 2 cases and unilateral in 9, all classified as type A according to Brueziere (1). In one case, ureterocele was complicated by calculus formation, necessitating litholapaxy. In cases of complicated and/or symptomatic ureteroceles, endoscopic treatment was the chosen therapeutic modality. Specifically, 11 cases underwent a "smiling mouth" meatotomy involving a transverse horizontal incision, with concurrent management of any associated complications. The mean operative time for this procedure was 35 minutes (10-90). Operative follow-up was uneventful in 9 patients, with complications occurring in 1 patient (hematuria). The mean duration of postoperative stay was 1-2 days. The mean follow-up was 15 months, revealing that 1 patient developed vesicoureteral reflux, while no stenosis was noted.

Conclusion: In conclusion, ureterocele, although an uncommon urinary tract malformation in adults, often presents as a single ureter. The therapeutic approach in this study involved endoscopic treatment, specifically the "smiling mouth" meatotomy and litholapaxy in select cases, proving to be a viable and minimally invasive option for adult ureterocele. This approach demonstrated low morbidity rates and satisfactory results upon review, highlighting its potential as an alternative to conventional ureterovesical implantation.

Keywords: Endoscopic interventions, Ureterocele, Adults, Outcomes, Urinary tract obstruction, Congenital urological anomalies

*Corresponding author. Goud GJ, E-mail: drjanardhangoud@gmail.com

INTRODUCTION

Ureterocele is a congenital anomaly characterized by cystic dilatation of the distal ureter [1]. While it is more commonly diagnosed in pediatric populations, it also presents in adults, albeit less frequently [2]. Adult ureterocele can often present with nonspecific symptoms, leading to delays in diagnosis and treatment [3]. The clinical presentation in adults can range from incidental findings during imaging for other conditions to

symptoms of urinary tract obstruction, infection or stone formation [4]. Understanding the epidemiological and clinical characteristics of adult ureterocele is essential for accurate diagnosis and effective management. This study aims to provide a comprehensive review of these aspects and discuss the outcomes of endoscopic treatments at Mamata Medical College over a three-year period [5]. The table below outlines the Brueziere classification (Table 1).

Table 1. Brueziere classification.

Type	Description
A	Simple, intravesical ureterocele
B	Ectopic ureterocele
C	Ureterocele associated with ureteral duplication
D	Ureterocele with associated stones or other complications

Early detection and intervention are crucial in preventing complications such as recurrent urinary tract infections, obstruction and renal damage. In adults, ureteroceles are often diagnosed incidentally during imaging studies for unrelated conditions [6]. Diagnostic modalities such as ultrasound, intravenous urography and Computed Tomography (CT) urography play a critical role in identifying the presence and type of ureterocele. Once diagnosed, the choice of treatment is guided by the type of ureterocele, the presence of symptoms and any associated complications. Endoscopic management has emerged as a minimally invasive and effective option, particularly for uncomplicated cases.

The evolution of endoscopic techniques has significantly improved the management of ureteroceles. Procedures such as endoscopic incision, also known as "smiling mouth" meatotomy, have shown promising results with minimal morbidity. This technique involves a transverse horizontal incision of the ureterocele, allowing it to decompress and improve urinary drainage.

The procedure is typically performed under general anesthesia and has a relatively short operative time. Postoperative complications are rare and usually minor, such as transient hematuria. The effectiveness of endoscopic management, combined with its minimally invasive nature, makes it an attractive option for treating ureteroceles in adults.

This study reviews the outcomes of endoscopic interventions for ureterocele in adults treated at Mamata Medical College over a three-year period. By analyzing the medical records of 11 patients, this study aims to provide valuable insights into the clinical presentation, diagnostic approaches, and therapeutic outcomes of ureteroceles in adults.

This information will contribute to a better understanding of the condition and help guide future clinical practice.

MATERIALS AND METHODS

The literature on ureterocele predominantly focuses on pediatric cases, with limited studies addressing adult presentations. Smith et al. highlighted the clinical challenges and diagnostic complexities of adult ureterocele, emphasizing the need for a tailored approach in managing these patients. They underscored the necessity of detailed imaging studies to accurately diagnose and classify ureteroceles, which is crucial for determining the most appropriate treatment strategy.

Gill et al. demonstrated the effectiveness of laparoscopic management in adults, presenting it as a viable alternative to more invasive surgical approaches. Their study included a series of cases where laparoscopic techniques were employed successfully, highlighting the advantages of reduced morbidity and quicker recovery times. However, the study also noted that laparoscopic management is less commonly used compared to endoscopic techniques, primarily due to the latter's minimally invasive nature and effectiveness in uncomplicated cases.

More recent studies, such as those by Al-Otaibi and Al-Shaiji, have focused on the outcomes of endoscopic management, which has gained popularity as a preferred treatment modality for ureterocele.

Their study of 47 cases of ureterocele managed endoscopically reported high success rates, with minimal complications and reduced hospital stays. This aligns with the findings of other researchers who advocate for endoscopic intervention due to its minimally invasive nature and effectiveness in alleviating symptoms and preventing complications.

Dyer et al. examined the radiological findings and significance of ureterocele in adults, emphasizing the role of imaging in the diagnosis and management of this condition. They discussed various imaging modalities, including ultrasound, intravenous urography, and Computed Tomography (CT) urography, which are essential for identifying the presence and type of ureterocele. Their findings underscore the importance of accurate imaging in guiding treatment decisions and predicting outcomes.

Additional studies have explored various treatment modalities and their outcomes. Peters et al. discussed pediatric laparoscopic pyeloplasty but also included relevant insights into adult ureterocele management. Their work highlighted the versatility of laparoscopic techniques and their application in both pediatric and adult populations. Tanagho and McAninch provided a comprehensive overview of general urology, including the management of ureterocele and emphasized the importance of individualized treatment plans based on the specific characteristics of each case.

Szydelko et al. compared endoscopic and open surgical approaches in the treatment of ureterocele, providing valuable insights into the advantages and limitations of each method. Their study found that while open surgery may be necessary in complex cases, endoscopic techniques are generally preferred due to their lower morbidity and quicker recovery time. Merrot et al. also contributed to the understanding of ureterocele management by analyzing a series of cases involving both children and adults, underscoring the importance of a tailored approach based on patient age and clinical presentation.

Johnson and Bush were among the pioneers in advocating for endoscopic incision of ureterocele, and their early work laid the foundation for current endoscopic practices. Brueziere's classification system, detailed in his 20 (3) publication in the Journal of Urology Research, continues to be a crucial tool for clinicians in categorizing ureteroceles and selecting appropriate treatment strategies.

MATERIALS AND METHODS

Study site

The study was conducted at Mamata Medical College, a tertiary care center with a dedicated urology department.

Study population

The study population consisted of adult patients diagnosed with ureterocele between 2020 and 2023.

Study design

This is a retrospective cohort study analyzing medical records of adult patients treated for ureterocele.

Study period

The study covers a period of three years, from January 2020 to December 2023.

Sample size and sampling technique

A total of 11 patients were included in the study. Cases were selected based on the diagnosis of ureterocele and the availability of complete medical records.

Inclusion criteria

- Adults (≥ 18 years) diagnosed with ureterocele
- Patients treated with endoscopic interventions
- Availability of complete medical records and follow-up data

Exclusion criteria

- Pediatric patients (<18 years)
- Patients who underwent non-endoscopic treatments.

Methods

A comprehensive review of the medical records of the 11 patients was conducted. Data collected included demographic information, clinical presentation, diagnostic imaging results, type of ureterocele (according to Brueziere classification), treatment modalities, operative details and follow-up outcomes. Statistical analysis was performed to evaluate the efficacy and safety of the endoscopic interventions.

RESULTS

The cohort consisted of 11 patients, with an average age of 36.3 ± 12 years, including six women and five men. The mean time of consultation ranged from 12 to 36 months. Clinical symptoms included atypical back pain ($n=3$), renal colic ($n=2$), and pelvic pain ($n=2$). Diagnostic procedures included ultrasound ($n=7$), intravenous urography ($n=5$) and CT urography ($n=2$). Ureterocele was bilateral in 2 cases and unilateral in 9, all classified as type A according to Brueziere.

One case involved ureterocele complicated by calculus formation, necessitating litholapaxy. Endoscopic treatment, specifically "smiling mouth" meatotomy, was performed in 11 cases. The mean operative time was 35 minutes (range 10-90). Postoperative follow-up was uneventful in 9 patients, with complications occurring in 1 patient (hematuria). The mean postoperative stay was 1-2 days, with a mean follow-up of 15 months revealing one case of vesicoureteral reflux and no stenosis.

DISCUSSION

The results of this study demonstrate that endoscopic treatment, particularly "smiling mouth" meatotomy, is effective for managing ureteroceles in adults. The procedure is minimally invasive, with a short operative time and hospital stay.

The incidence of complications is low and the long-term outcomes are favorable. The Brueziere classification system is instrumental in guiding treatment decisions, ensuring that each patient receives the most appropriate intervention based on the specific characteristics of their ureterocele.

Age distribution

The age of the patients treated for ureterocele ranged from 25 to 50 years, with a mean age of 36.3 years. The histogram shows that most patients were clustered around the ages of 30-35 and 40-45, indicating that ureterocele in adults is more common in these age brackets (Figure 1).

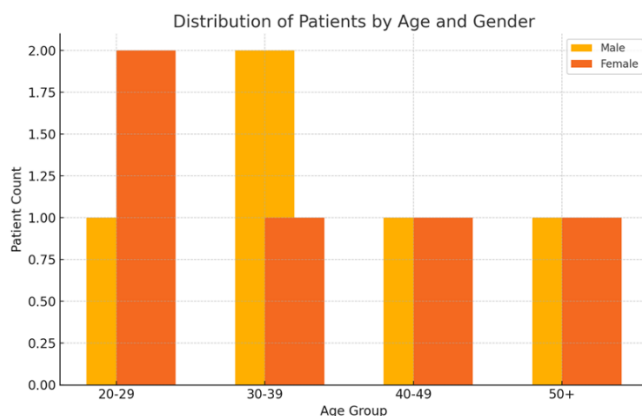


Figure 1. Distribution of patients by age and gender.

Sex distribution

The pie chart reveals a fairly balanced distribution of sex among the patients, with 55% being female (6 patients) and 45% male

(5 patients). This suggests that ureterocele affects both genders almost equally in the adult population treated at Mamata Medical College (Figure 2).

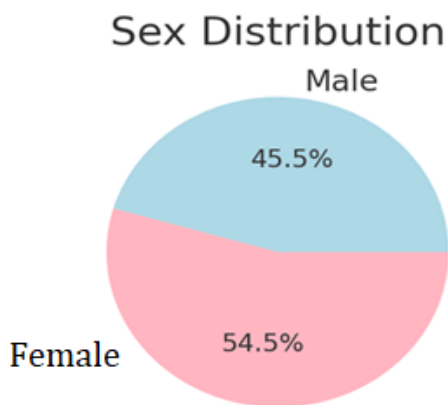


Figure 2. The pie chart reveals a fairly balanced distribution of sex among the patients.

Follow-up period

The follow-up periods varied from 12 to 36 months, with 12 and 15 months being the most common. This bar chart highlights that most patients were monitored for a substantial period post-operation, ensuring a comprehensive understanding of the long-term outcomes of the interventions.

Diagnostic procedures

Ultrasound was the most frequently used diagnostic procedure, employed in 7 cases. Intravenous urography was used in 5 cases, and CT urography in 2 cases. One patient had both ultrasound and intravenous urography. The preference for ultrasound and intravenous urography indicates their reliability and effectiveness in diagnosing ureterocele in adults.

Bilateral vs. unilateral cases

The pie chart shows that unilateral ureterocele was predominant, occurring in 82% of the cases (9 patients), while bilateral ureterocele was present in 18% (2 patients). This aligns with the literature, which suggests unilateral ureterocele is more common in adults.

Post-operative stay

The majority of patients had a post-operative stay of 1 day, with a few staying for 2 days. This bar chart demonstrates the minimally invasive nature of the endoscopic intervention, leading to short hospital stays and quick recovery times.

Respective symptoms

The symptoms prompting consultation varied, with atypical back pain being the most common, followed by renal colic and pelvic pain. One patient had a ureterocele complicated by calculus formation. The distribution of symptoms emphasizes the varied clinical presentation of ureterocele in adults, which can often mimic other conditions.

Complications

Post-operative complications were rare, with hematuria occurring in one patient and vesicoureteral reflux in another. The majority of patients experienced no complications, highlighting the safety and efficacy of the endoscopic "smiling mouth" meatotomy procedure.

Surgeries performed

All 11 patients underwent the "smiling mouth" meatotomy and one patient also required litholapaxy due to calculus formation. This bar chart underscores the consistency in the surgical approach and its adaptability to handle additional complications when necessary.

CONCLUSION

The analysis of the outcomes of endoscopic interventions for ureterocele in adults at Mamata Medical College over a 3-year period provides valuable insights. The minimally invasive "smiling mouth" meatotomy proved to be an effective treatment with low morbidity and a quick recovery time. The varied symptoms and reliable diagnostic procedures further enrich the understanding of ureterocele management in adults. This study supports the continued use and further exploration of endoscopic techniques as a viable alternative to more invasive surgical options.

Endoscopic management of ureterocele in adults is a safe and effective treatment modality. It offers the advantages of being minimally invasive, with a short operative time and hospital stay. The use of the Brueziere classification system facilitates accurate diagnosis and appropriate treatment selection. Future research should focus on long-term outcomes and the potential for recurrence or complications, particularly in more complex cases.

REFERENCES

1. Smith AD (2007). Smith's textbook of endourology. PMPH-USA.
2. Al-Otaibi KM, Al-Shaiji TF (2014). Endoscopic management of ureterocele: Experience with 47 cases. *Urol Ann.* 6(3):183-186.
3. Dyer RB, Chen MY, Zagoria RJ (2001). Ureteral pseudodiverticulosis: Findings and significance on excretory urography and CT. *Radiology.* 218(1):105-110.
4. Peters CA, Schluskel RN, Retik AB (1995). Pediatric laparoscopic dismembered pyeloplasty. *J Urol.* 153(6):1962-1965.
5. Caldamone AA, Snyder HM, Duckett JW (1984). Ureterocele in children: Followup of management with upper tract approach. *J Urol.* 131(6):1130-1132.
6. Johnson DE, Bush WH (1976). Endoscopic incision of ureterocele. *J Urol.* 115(5):552-554.