

Case Report

Sigmoid sinus vein thrombosis in a case of surgically treated hemorrhagic herpes encephalitis

Or Cohen-Inbar^{1*} and Menashe Zaaroor²

¹Neurosurgical Department Rambam Health Care Campus, P.O. Box 9602 Haifa 31096 Israel. Molecular Immunology Laboratory, Technion Institute of Technology, Haifa, Israel. ²Department of Neurosurgery, Faculty of Medicine, Technion Israel Institute of Technology, Rambam Maimonides Health Care Campus, Haifa, Israel.

Accepted 17 May, 2021

A temporal massive hemorrhagic necrosis is an uncommon but known complication of herpes encephalitis. Cerebral vein or sinus thrombosis is a very rare complication of herpes encephalitis. Due to its rarity, this complication can go under-diagnosed, resulting at times in grave neurological deficits for the patient. The concurrent existence of both complications is even less common and difficult to diagnose. This also complicates the medical management of the patient due to contradicting considerations. We report a case of a twenty years old female, admitted with herpes encephalitis. The clinical course was complicated by a right temporal lobe massive hemorrhagic necrosis and a late sigmoid sinus vein thrombosis. Intravenous heparin, administered for the thrombosis resulted in further deterioration with evidence of increased hemorrhagic mass lesions, elevated intracranial pressure, uncal herniation and a right "blown pupil". The patient underwent a decompressive craniectomy with dural fenestrations. The patients quickly recovered, regained consciousness and was weaned off respirator. Anticoagulant therapy was reinstated within 48 h of surgery with no further complications. We advocate a high index of suspicion (clinical and radiological) for both hemorrhagic and thrombotic complications in herpes encephalitis patients, and a judicious use of anticoagulation. A multidisciplinary team approach and an early neurosurgical consult in such patients should be the routine.

Key words: Temporal, hemorrhagic necrosis, herpes encephalitis, cerebral vein thrombosis, sinus thrombosis.

INTRODUCTION

The morbidity and mortality of herpes simplex encephalitis has decreased in past years, with the widespread application of antivirals, the liberal use of imaging, heightened awareness and better patient monitoring. Still, this figure remains stable for the last few

years. (Gonzalez et al., 2008) Possible explanations to this fact stems from the different complications this infection invokes. One cause of morbidity is the development of focal hemorrhagic necrosis and edema in the temporal lobes, giving rise to space-occupying lesions, with a subsequent elevation of intracranial pressure. (Gonzalez et al., 2008). Overt hemorrhage is infrequent in herpes simplex virus encephalitis but can lead to poor outcomes (Tonomura et al., 2010). In some cases, the hemorrhagic necrosis and edema can be refractory to medical treatment, with fatal outcome (Gonzalez et al., 2008). These symptoms may appear as

*Corresponding author. E-mail: orcoheni@tx.technion.ac.il, Or_coheni@rambam.health.gov.il, orcoheninbar@gmail.com.
Tel: +972-4-8541840, +972-50-2066095. Fax: +972-4-8543664/
+972-4-8293779.

the presenting manifestations of the infection, without the dermatological vesicular rash or fever as warning signs. As opposed to hemorrhagic necrosis of the temporal lobe, cerebral vein thrombosis (CVT) as well as sinus vein thrombosis (SVT) has not been described as a common complication of herpes encephalitis. To the best of our knowledge, a single case is reported, in which a patient was diagnosed with acute herpes encephalitis developed a CVT with a small hemorrhagic component (Chan et al., 2005). This patient was treated conservatively. Chan et al. (2004) described a lateral sinus thrombosis that developed during the clinical course of zoster sine herpette in the C2 distribution. No hemorrhagic necrosis or other neurologic deficit was described. CVT is a serious and potentially fatal type of stroke. Overall, CVT is uncommon, with an annual incidence of 3.4/100,000 per year in our population (Boussier et al., 1985; Breteau et al., 2003; Chan et al., 2005; Mak et al., 2001; Tanislav et al., 2011). Thrombosis may produce venous congestion with a resultant rise in intracranial pressure (ICP), cerebral ischemia and venous infarction. Patients may present with diffuse or localised headache, features of raised ICP, focal or generalised seizures, lethargy or coma, non-specific visual obscurations, transient visual loss, and alternating hemiparesis or paraparesis (Ameri and Boussier, 1992; Boussier et al., 1985; Breteau et al., 2003; Chan et al., 2005; Mak et al., 2001; Tanislav et al., 2011). These non-specific clinical features can be attributed many other disorders such as idiopathic intracranial hypertension, viral encephalitis, dural arteriovenous fistula, other causes of cerebral infarcts or intracerebral haemorrhages (Boussier et al., 1985; Breteau et al., 2003; Chan et al., 2005; Chan et al., 2004; Mak et al., 2001; Tanislav et al., 2011). The natural history and long-term prognosis of cerebral vein and dural sinus thrombosis (CVT) have been examined prospectively (Ferro et al., 2004). Multivariate negative prognostic signs were age older than 37 years, male sex, coma on admission, cerebral hemorrhage on admission, thrombosis of the deep venous system, central nervous system infection and cancer. Taken this data into account, it seems that patients with herpes encephalitis suffering a temporal lobe hemorrhagic necrosis and concurrent CVT suffer a grim prognosis due a multitude of etiologies. Under these circumstances, some authors proposed taking an aggressive treatment strategy in these patients, both surgically and medically, utilizing decompressive craniectomy to treat severe intracranial hypertension and prevent serious neurologic deficits. Gonzalez et al. (2008) decompressive craniectomy has shown to be a very effective tool in the acute management of ICP and in decreasing mortality (but not morbidity) in traumatic brain injury (TBI) patients (Soustiel et al., 2010).

We describe a case of a healthy 20 years old female suffering from herpes simplex encephalitis that presented with fever headache and convulsions, developing a massive temporo-frontal hemorrhagic necrosis and a late sigmoid sinus thrombosis. The patient was treated

aggressively both medically and surgically.

CLINICAL SUMMARY

A twenty years old young woman of Arab descent, not known to suffer any chronic illnesses immunodeficiency or coagulation disorders presented to a country hospital complaining of diffuse headache, high fever and a focal secondary generalized seizure. Physical and ophthalmological examinations findings included nuchal rigidity and a mild papilledema with a blurred optic disc. Initial lumbar puncture study performed showed a mild pleocytosis, chemical parameters normal (normal glucose and protein levels). Electroencephalogram (EEG) showed generalized slowing, allowing for the diagnosis of meningoencephalitis. Initial empirical anti-herpetic treatment with acyclovir was initiated. Polymerase chain reaction (PCR) test for Herpes simplex, done on cerebrospinal fluid from the initial tap prior to treatment initiation, was later revealed as positive. We do report that multiple blood and spinal fluid samples taken after the initial one were negative for the virus. A few days after admission, under conservative treatment, a progressive neurological deterioration ensued, with a deteriorating consciousness. The patient was transferred to our referral tertiary medical center. Admission non contrast enhanced computed tomography (CT) showed right temporal lobe hemorrhagic necrotic lesions measuring thirty and fifteen millimeters (Figure 1B). A vasogenic edema around the hemorrhagic lesions was evident, with radiological signs of an uncal subfalcine herniation. Initial CT-Angio (CTA) was interpreted as normal, no signs of arteriovenous malformation, aneurysm or a CVT. Electroencephalogram showed evidence of paroxysmal epileptiform activity. The medical treatment was augmented by mannitol at moderate levels (not more than 10 mg/kg/day in divided doses), valproic acid at therapeutic levels with transient clinical improvement. A gadolinium enhanced MRI showed no new findings at that time.

The next 3 days were characterized by a slow clinical deterioration in consciousness, up to mild drowsiness without convulsions or fever. Follow-up non-contrast enhanced tomography performed daily showed a mildly increased mass effect secondary to increasing vasogenic edema around the hemorrhagic lesions. After three days, a CTA performed showed radiological evidence of a left sigmoid sinus thrombosis (Figure 1A). Intravenous heparin was instituted but promptly discontinued after a few hours due to a sudden severe decrease in consciousness with unisocoria and a right "blown pupil". CT showed increased cerebral parenchymal hemorrhage at the right temporal previous foci (Figure 1C, 1D). The patient was rushed to the operating theater and a right decompressive craniectomy with dural fenestration and ICP catheter insertion was performed (Figure 1C, 1D).

The patient was then admitted to the neurosurgical intensive care unit and later the neurosurgical department. Post-operatively, the ICP measurements were within normal range although waveform anatomy distortion was noted due to the lack of the closed box effect of the skull. The patient underwent an early tracheostomy and was shortly after weaned of ventilator. During the next few days, the patient quickly regained consciousness; no focal motor deficits were noted. Anticoagulant treatment was re-instituted within 48 h of surgery. Follow-up imaging showed a steady absorption of the hemorrhagic lesions. The patient was transferred to a rehabilitation institute within 12 days of the surgery fully alert and conscious, requires some assistance in daily activities but steadily improving.

Conclusions

CVT although rare and uncommon, can complicate the clinical course of patients suffering from Herpes encephal-

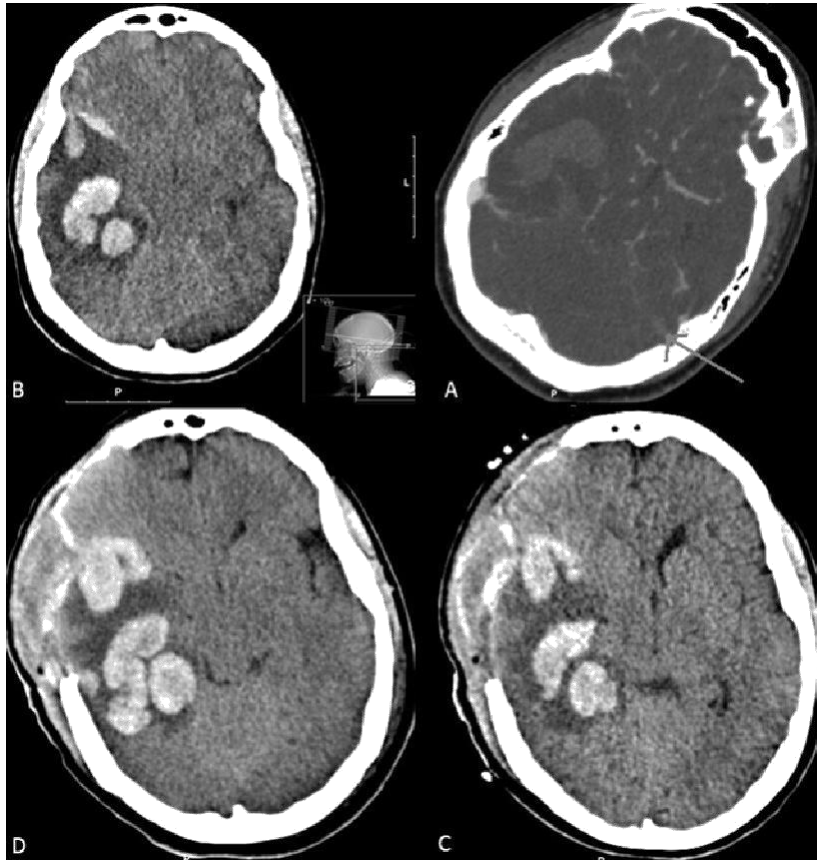


Figure 1. A- CT-Angio in venous phase showing a right temporal intracerebral Hemorrhage and a filling defect in the left sigmoid sinus marked with an arrow correlating to a sinus vein thrombosis. See the right sigmoid sinus bulb filled with contrast for comparison; B- A non contrast enhanced CT showing the Intra-cerebral hemorrhages. See the mild hyperdensity seen in the ri; C and D- A non contrast enhanced post-operative CT of the same patient. After undergoing a right frontal decompressive craniectomy showing a mild enlargement of the parenchymal hematoma after decompression.

litis, with or without hemorrhagic necrosis. One should bear in mind that the course of herpes encephalitis can be complicated by both thrombotic and hemorrhagic intracranial complications, each warranted by aggressive treatment of the other. The central nervous system has a very high concentration of tissue factor, released to the circulation upon any trauma (predisposing trauma patients for both thrombosis and disseminated intravascular coagulation). Still, whether the herpes virus itself, the encephalitic process, or the bedridden status of the patient predisposes for cerebral venous thrombosis remains to be proven. A balanced clinical reasoning and a high clinical suspicion is mandated. The liberal use of appropriate imaging should be the rule. Upon CVT diagnosis, the medical management looks less favorably on conventional anticoagulation due to the risk of a late parenchymal hemorrhage or hemorrhagic transformation. An early neurosurgical and interventional neuro-radiological consult is recommended. In addition to

described conventional treatment modalities, decompressive craniectomy and angiographic thrombectomy are relevant treatment options for selected patients. Thus, a multidisciplinary team approach seems to be advisable.

REFERENCES

- Breteau G, Mounier-Vehier F, Godefroy O (2003). Cerebral venous thrombosis: 3-year clinical outcome in 55 consecutive patients. *J. Neurol.* 250:29-35.
- Chan J, Bergstrom RT, Lanza DC (2004). Lateral sinus thrombosis associated with zoster sine herpette. *Am. J. Otolaryngol.* 25:357-360.
- Chan KH, Cheung RT, Liu WM (2005). Cerebral venous thrombosis in a gentleman presenting with fever, convulsion and frontotemporal haemorrhages. *J. Clin. Neurosci.* 12:186-188.
- Chan KH, Cheung RT, Mak W (2004). Cerebral venous thrombosis presenting as unilateral headache and visual blurring in a man with nephrotic syndrome. *Hosp. Med.* 65:54-55.
- Ferro JM, Canhao P, Stam J (2004). Prognosis of cerebral vein and dural sinus thrombosis: Results of the International Study on Cerebral Vein and Dural Sinus Thrombosis (ISCVT). *Stroke* 35:664-670.

- Gonzalez RGA, Fons C, Rey A (2008). Craniectomy in herpetic encephalitis. *Pediatr. Neurol.* 39:201-203.
- Mak W, Mok KY, Tsoi TH (2001). Cerebral venous thrombosis in Hong Kong. *Cerebrovasc. Dis.* 11:282-283.
- Soustiel JF, Sviri GE, Mahamid E (2010). Cerebral blood flow and metabolism following decompressive craniectomy for control of increased intracranial pressure. *Neurosurgery* 67:65-72.
- Tanislav C, Siekmann R, Sieweke N (2011). Cerebral vein thrombosis: Clinical manifestation and diagnosis. *BMC Neurol.* 11:69.
- Tonomura Y, Kataoka H, Yata N (2010). A successfully treated case of herpes simplex encephalitis complicated by subarachnoid bleeding: A case report. *J. Med. Case Reports* 4:310.
- Ameri A, Bousser MG (1992). Cerebral venous thrombosis. *Neurol. Clin.* 10:87-111.
- Bousser MG, Chiras J, Bories J (1985). Cerebral venous thrombosis: A review of 38 cases. *Stroke* 16:199-213.