

Full Length Research Paper

The Acute brain swelling due to remote epidural hematoma during lateral ventricle tumor resection

Lunshan Xu, Minhui Xu*, Yongwen Zou, Guangxin Chen and Hong Liang

Department of Neurosurgery, Institute of Surgery Research; Daping Hospital, Third Military Medical University; Chongqing 400042, China.

Accepted 10 May, 2021

We report a very rare case of epidural hematoma, which occurred in the right hemisphere during a left lateral ventricle tumor resection. A 37-year-old female patient underwent elective surgery for removal of a lateral ventricle meningioma. Intraoperatively, the patient suffered from acute brain swelling close half an hour after tumor removal. Numerous measures were taken to reduce the brain swelling. A remote epidural hematoma was confirmed by a CT scan. Complete excision of the tumor was achieved after removal of the epidural hematoma. The management of the case was discussed in this paper.

Key words: Brain swelling, epidural hematoma, lateral ventricle tumor resection.

INTRODUCTION

Malignant edema can turn a meticulous operation into a life-threatening emergency, which is commonly seen after traumatic brain injury, as compared to elective neurosurgical operations. In the latter, brain swelling may be caused by hemorrhage secondary to aneurysm rupture or intracranial hematoma during resection of brain tumors. The brain may suddenly swell and is uncontrollable so that the surgery has to be discontinued due to lack of access to the intracranial surgical site. We encountered acute intraoperative brain edema in a patient undergoing elective surgery for removal of a lateral ventricle meningioma. Total excision of the remaining tumor was achieved after the removal of the epidural hematoma was confirmed by an urgent CT scan. The possible cause and management were discussed.

PATIENT AND METHODS

General data

A 38-year-old female was admitted in Daping hospital due to headache and impaired concentration for 3 years. During the week

before hospitalization, the situation deteriorated. On neurological examination, bilateral papilledema was observed, but there was no abnormal neurological reflex. All routine preoperative investigations were within normal ranges. Magnetic resonance imaging (MRI) revealed a lesion with isointensity and slight hypointensity to the gray substance on T₁-weighted images (Figure 1) and hyperintensity to the gray substance on T₂-weighted images. A solid, homogenous contrast-enhancing lesion of 4.2*5.6*4.8 cm was observed in the trigonum of the left lateral ventricle. Based on these findings, the diagnosis of left lateral ventricle meningioma was discovered.

Procedures

Left-side parietooccipital craniotomy was performed to completely remove the tumor. The patient was fixed in a lateral position with 15° head-up-tilt on a Mayfield pin headrest. After craniotomy, the lesion was found to be just below the surface under neuronavigation, and it was moderately vascular, with a well-defined margin. A close one half excision of the tumor was in process within two hours after skin incision. Suddenly, we noticed the intracranial surgical site lessened and the brain bulged beyond the craniotomy margins. The head position was checked to rule out carotid vein compression. Measures including administration of mannitol (75 mg), furosemide (20 mg), dexamethasone (20 mg), and hyperventilation were taken to reduce brain edema. Inhalation anesthesia discontinued and total intravenous anesthesia was performed using propofol. Meanwhile, we failed to locate any active bleeding site. Despite the measures aforementioned, brain edema was not effectively improved. Then, an urgent computerized tomography (CT) scan was conducted. The scalp was tacked with interrupted suture over the widely opened

*Corresponding author. E-mail: chxxu-meed@foxmail.com. Tel: +8623-68757976.

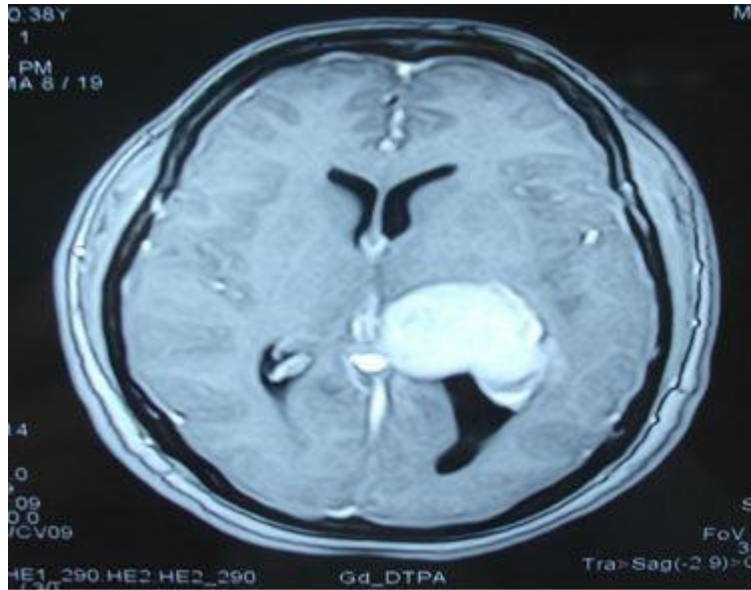


Figure 1. T1-weighted image in contrast enhanced MR,I which revealed a solid tumor within the left trigonum of lateral ventricle with hyperintense.

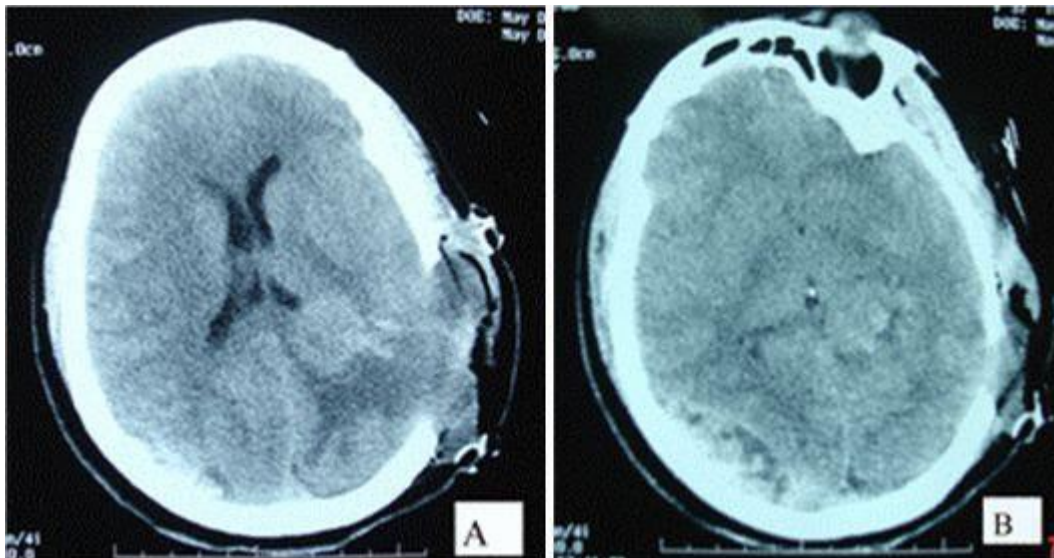


Figure 2. CT scan after the first surgery demonstrated close to the one half excision of the lesion associated with epidural hematoma. (A) An epidural hematoma in the right occipital region associated with brain herniation; (B) a distinct epidural hematoma in the right occipital region.

dura mater, and the patient was shifted for CT under ventilatory support. An epidural hematoma of about 90 ml was found in the right occipital region, distant from the surgical site (Figure 2 and 3A). The patient was transferred back to the operation room, and then the hematoma was removed (Figure 3B). Subsequently, we preferred to proceed with the completion of tumor excision with his head turned to the right in a supine position. The remaining tumor was coagulated and divided, and then piecemeals were excised piecemeally. Due to extrusion of the brain beneath the craniotomy margins, the dura

mater was closed primarily, and the bone flap was replaced (Figure 4).

RESULTS

The postoperative course of this patient was uneventful. Four hours later, the trachea was extubated after

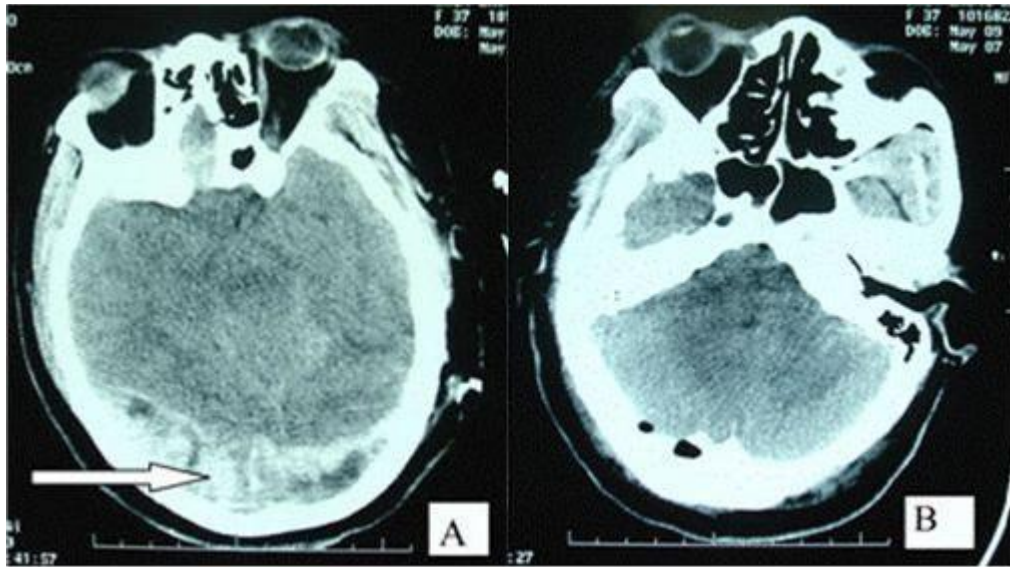


Figure 3. CT manifestations of the epidural hematoma. (A) CT scan after the first surgery demonstrated epidural hematoma in the right occipital region distant from the surgical site. The arrow indicates the extradural hematoma; (B) CT scan after the second surgery demonstrated epidural hematoma which was removed completely with alveoli.

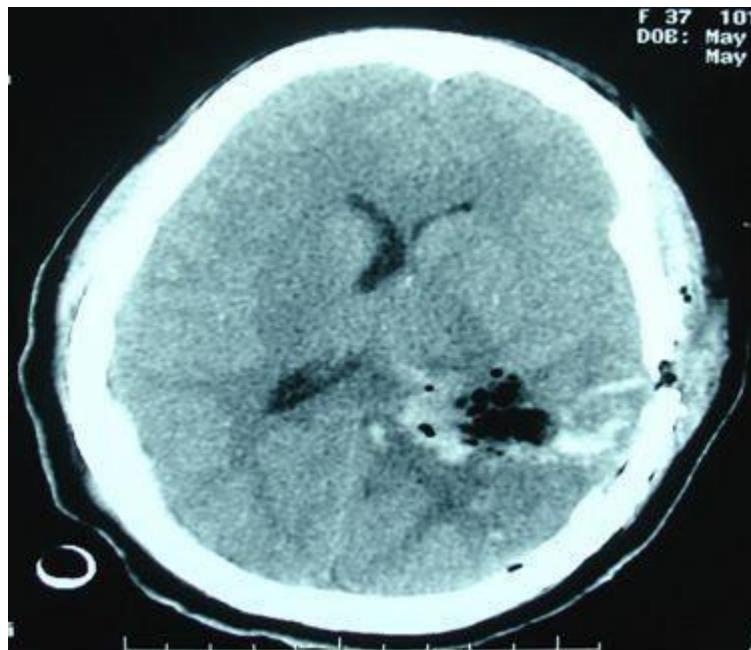


Figure 4. The first CT scan of the head post-operation demonstrated the complete excision of the lesion with the bone flap reserved.

spontaneous neuromuscular reversal. Motor function test revealed equal strength bilaterally. Although mental functions were normal, the patient suffered from speech disturbance and homonymous hemianopia, which lasted

till the time of discharge. Histological examination showed that it is a fibroblastic meningioma. A plain CT scan of the head was performed on the 2nd day postoperatively and the results demonstrated the complete excision of the

lesion. A MRI was not carried out, due to patient's refusal. She discharged on the 10th day postoperatively. Three months after surgery, the patient received evaluation and results indicated that the speech disturbance of the patient has finally resolved, with mild homonymous hemianopia.

DISCUSSION

The exact mechanism underlying the occurrence of acute open brain herniation during elective neurosurgery remains unknown. Under such an emergent situation, the causes of anesthetic and intracranial need to be checked rapidly and ruled out, as persistent brain edema can lead to irreversible neurological damage and even brain rupture. Acute intracranial hypertension caused by either subarachnoid or delayed intracranial hematomas together with hyperemia, as well as severe edema around huge intracranial meningiomas, has been proposed as the primary cause (Whittle and Vishwanathan, 1996; Li et al., 2005). Possible anesthetic factors such as hypercarbia, hypoxia, over-hydration and improper position of the head leading to impaired cerebral venous drainage should be considered and corrected (Procaccio et al., 2000).

Simultaneously, the hemorrhage into the tumor cavity also observed to be ruled out. Other situations that cause brain edema include excision of vascular tumors, tumors involving deep venous structures, evolving distant hematoma and rupture of aneurysms with subarachnoid hemorrhage. Another cause of open brain herniation may be brain shrinkage and shift consequent upon tumor decompression that may tear draining veins, thus leading to contralateral subdural hematoma (Ohigashi and Tanabe, 2001). Contralateral epidural hematoma should always be considered after ipsilateral decompression of acute subdural hematoma, especially in cases of intraoperative brain swelling and skull fractures. In this patient with intracranial hypertension, the sudden decreased in intracranial pressure which is caused by removing cerebrospinal fluid excessively or too fast, may be the cause of remote epidural hematoma. Intracranial hemorrhage occurred often when the intracranial pressure decreased too fast to cause spontaneous dural collapse, which further led to severe hemorrhage. There is no aneurysm between the dura and the skull. The patient recovered postoperatively, and no other organic diseases were found.

Acute brain swelling is associated with high mortality and disability. The treatment of choice remains controversial. The main goal in the management of intraoperative brain herniation during elective neurosurgery is to leave an opportunity to the next therapy that is more definitive. The patient was immediately placed on a head-up tilt position and received rapid administration of mannitol. Hyperventilation is thought as one of the

strategies to improve brain edema, but poorly validated in part of neuroanesthetic practices. This strategy, however, carries the potential risk of reducing cerebral oxygenation by excessive reduction of cerebral blood flow in the normal brain as well. Therefore, it is recommended for short term application (Gelb et al., 2008). Volatile anesthetics were discontinued and total intravenous anesthesia was performed using propofol, which is thought to have the potential to reduce increased intracranial pressure (ICP) (Cole et al., 2007). Induced hypotension technique and improvement of cerebral anoxia are also effective methods for the prevention and treatment of acute intraoperative encephalocele.

Yet, the surgical management of open brain herniation is controversial. Potential management must be based on accurate diagnosis. Intraoperative sonography or CT may have some advantages. The CT scan can reveal the presence of hematoma or subarachnoid hemorrhage associated mild hydrocephalus, which may be the causes of brain swelling. Some surgeons have to perform a lobectomy to prevent the rupture of herniating brain, but it may result in loss of some neurological functions. Moreover, resection of normal brain does not prevent continuous herniation in the case of contra-lateral hematoma. The possibility of hematoma should be considered when there is any sudden brain swelling during operation, and an emergency CT scan should be performed after the scalp has been tacked with interrupted suture over the widely opened dura mater (Ohata et al., 2008). For this patient, emergency surgery is the treatment of choice for such large hematoma. The overall prognosis of patients with intraoperative brain herniation due to extra-axial subarachnoid or intraventricular hemorrhage is better as compared to brain herniation secondary to intraparenchymal hemorrhage or diffuse brain edema (Whittle and Viswanathan, 1996). We preferred to continue tumor excision, rather than staging operation, because intraventricular meningiomas are relatively resistant to most forms of therapy other than excision, and complete removal often results in cure or provides a long term palliation. The patient's postoperative course was uneventful, but she had an incomplete expressive aphasia, which could be attributed to herniation of brain restricted to bone margin, other than iatrogenic sequela (Tew and Larson, 2000).

In summary, we report a case of intra-operative brain swelling in a patient undergoing excision of the brain tumor caused by remote epidural hematoma, which was confirmed by an urgent CT scan. The occurrence of the epidural hematoma is one of the curable causes for unknown brain swelling during brain tumor surgery. We strongly recommended that any sudden brain swelling during the operation should be thought of the possibility of hematoma and urgent CT scan should be carried out after the scalp is tacked with interrupted suture over the widely opened dura mater.

REFERENCES

- Cole CD, Gottfried ON, Gupta DK, Couldwell WT (2007). Total intravenous anesthesia: advantages for intracranial surgery. *Neurosurgery.*, 61: 369-377.
- Gelb AW, Craen RA, Rao GS, Reddy KR, Megyesi J, Mohanty B, Dash HH, Choi KC, Chan MT (2008). Does hyperventilation improve operating condition during supratentorial craniotomy? A multicenter randomized crossover trial. *Anesth Analg.*, 106: 585-594.
- Li XY, Wang ZC, Liu Y, Chen YS, Zhuo ZP (2005). Study of small dural window exposure strategy for preventing intraoperative acute brain herniation during removal of huge intracranial meningiomas. *Zhongguo Wei Zhong Bing Ji Jiu Yi Xue*, 17: 496-499.
- Ohata H, Yamada T, Dohi S (2008). Postoperative epidural hematoma remote from the site of craniotomy for STA-MCA anastomosis, 57: 756-760.
- Ohigashi Y, Tanabe A (2001). A huge frontal meningioma associated with intraoperative massive bleeding and severe brain swelling: Case report. *J. Clin. Neurosci.*, 8: 54-58.
- Procaccio F, Stocchetti N, Citerio G, Berardino M, Beretta L, Della Corte F, D'Avella D, Brambilla GL, Delfini R, Servadei F, Tomei G (2000). Guidelines for the treatment of adults with severe head trauma (part II) Criteria for medical treatment. *J. Neurosurg. Sci.*, 44: 11-18.
- Tew JM, Larson JJ (2000). Jr: Intraventricular meningiomas, in Kaye AH, Black PML (eds): *Operative Neurosurgery*. London: Churchill Livingstone, pp. 575-585.
- Whittle IR, Vishwanathan R (1996). Acute intraoperative brain herniation during elective neurosurgery: Pathophysiology and management considerations. *J. Neurol. Neurosurg. Psychiatry*, 61: 584-590.